



Rescue and rehabilitation of maned wolf (*Chrysocyon brachyurus*) in Paraguay: Case description

Joerg Richard Vetter Hiebert¹  | José Gaspar Petters Cabrera² |
Santiago Benítez del Puerto³ | Roger González Vatteone⁴ | Marlene Florentín Morel⁵ |
Diego Augusto Dacak Aguilera⁵ | César Esteban Brítez Valinotti⁶ |
Raquel Ramírez Diarte⁷ | Lilian Maria González González⁸ | Carlos Coronel Díaz⁹ |
Paola Osorio¹⁰ | Walter Cardozo¹¹ | Fátima Bracho¹² | Claudia Raquel Soto¹² |
Nilsa Melissa Domínguez Barreto¹² | Antonio Alejandro Sciabarrasi^{13,14} 

¹Departamento de Recursos Faunísticos y Medio Natural, Facultad de Ciencias Veterinarias, Universidad Nacional de Asunción, San Lorenzo, Paraguay

²Servicio Nacional de Calidad y Salud Animal (SENACSA), San Lorenzo, Paraguay

³IMAVET, Veterinary Ultrasonography Area, Asunción, Paraguay

⁴Facultad de Ciencias Veterinarias, Cátedra de Técnica Operatoria, Universidad Nacional de Asunción, San Lorenzo, Paraguay

⁵Clínica Veterinaria Diego Dacak, Asunción, Paraguay

⁶Centro Veterinario VETCIA, Asunción, Paraguay

⁷IMAVET, Veterinary Radiology Area, Asunción, Paraguay

⁸Centro de Especialidades Veterinarias (CEV), Veterinary Cardiology Area, Asunción, Paraguay

⁹Ministerio del Ambiente y Desarrollo Sostenible, Dirección General de Protección y Conservación de la Biodiversidad, Dirección de Vida Silvestre, Asunción, Paraguay

¹⁰Independent Veterinarian, Asunción, Paraguay

¹¹Laboratorio LAVETAVALOS, Asunción, Paraguay

¹²Facultad de Ciencias Veterinarias, Universidad Nacional de Asunción, San Lorenzo, Paraguay

¹³Facultad de Ciencias Veterinarias, Universidad Nacional del Litoral, Santa Fe, Argentina

¹⁴Centro de rescate e interpretación de la Fauna La Esmeralda, Gobierno de Santa Fe, Argentina

Correspondence

Joerg Richard Vetter Hiebert, Departamento de Recursos Faunísticos y Medio Natural, Facultad de Ciencias Veterinarias, Universidad Nacional de Asunción, Highway PY02, km 10, Campus Universitario, San Lorenzo 111421, Central Paraguay.
Email: jvetter@vet.una.py

Abstract

The maned wolf, *Chrysocyon brachyurus*, is the largest South American canid, with a natural distribution that stretches across Peru, Bolivia, Brazil, Argentina, Paraguay and Uruguay. The present study reports the case of a rescued specimen of maned wolf that underwent a rehabilitation process in Paraguay, starting in October 2020 with its rescue, and finalising in May 2021 with the reintroduction. Herein, we document findings regarding the general management, biometrics, feeding and environmental enrichment; chemical immobilisation and monitoring; haematology, blood biochemistry and specific serology-relevant pathogens; skin examination and bone marrow cytology; orthopaedic, ophthalmological and dental evaluation; abdominal and cardiac ultrasonography; radiology and copro-parasitology. Main findings include the feeding habits

This is an open access article under the terms of the [Creative Commons Attribution-NonCommercial-NoDerivs](https://creativecommons.org/licenses/by-nc-nd/4.0/) License, which permits use and distribution in any medium, provided the original work is properly cited, the use is non-commercial and no modifications or adaptations are made.

© 2024 The Authors. *Veterinary Medicine and Science* published by John Wiley & Sons Ltd.

of the individual and enrichment opportunities. The animal weighed 7 kg on arrival, with an estimated age of 5 months, and 18 kg on reintroduction, with an estimated age of 1 year. The animal tested negative to serologic tests for *Brucella canis*, *Dirofilaria*, canine distemper, *Toxoplasmosis* and canine parvovirus. *Leptospira* testing showed antibodies against *L. grippityphosa* on both samplings, *L. wolffi* and *L. ictero* on the first sampling, and *L. pomona* on the second sampling. Abdominal organs were examined and measured through ultrasound evaluation and kidneys showed no alterations. Echocardiography showed preserved mitral, tricuspid and aortic valve flows, but turbulent pulmonary valve flow. Copro-parasitology reported the presence of *Lagochilascaris* sp. and *Balantidium* sp. All the information gathered aided in diagnosing the health status of the individual, and the response to environmental enrichment helped assess the behaviour, which led to the suggestion of reintroducing the animal. These data constitute the first published health check of a maned wolf in Paraguay, which can contribute to the species' conservation in the country. The protocol presented in this study can serve as a basis for developing an action plan for the maned wolf in Paraguay.

KEYWORDS

biometrics, Boquerón, *Canidae*, *Lagochilascaris*, reintroduction

1 | INTRODUCTION

The maned wolf, *Chrysocyon brachyurus* (Illiger, 1815), is the largest canid in South America (Dietz, 1985). It is distinguishable from other South American canids, as an adult, by its fur that can vary from orange to golden red in colour, and the long mane that becomes more evident in the juvenile stage and lasts throughout life (Dietz, 1984).

The species natural distribution spans across Peru, Bolivia, Brazil, Argentina, Paraguay and Uruguay, although no local populations have been identified in the latter, considered to be critically endangered in the southern limit of its distribution (Kasper et al., 2023; Paula & DeMatteo, 2016; Queirolo et al., 2011). In Paraguay, the species is fairly widespread at low density within grassland and forest edge habitats, in the Oriental region, and more humid areas in the Occident (Paraguayan Chaco) region (Smith, 2022).

The species global conservation status is nearly threatened, its main threats being the loss of habitat, road kills, direct persecution by humans and pathologies associated with proximity to domestic animals (Paula & DeMatteo, 2016). In Paraguay, it is categorised as vulnerable, mainly due to a reduction of approximately 30% in the population size of the species within the country. It finds its main threats in the loss, degradation and fragmentation of its habitat, road kills, hunting due to conflict with poultry, colonisation of rural areas and the consequent displacement of the species, due to fires, parasitism and diseases acquired from household species (Giordano et al., 2017). Although some studies report on local (sub-national) distribution and richness of the species, there are no specific studies on the species in Paraguay (Areskoug, 2001; Zuercher et al., 2001; Salinas et al., 2022; Zuercher et al., 2003).

The maned wolf can be exposed to various pathogens both in natural environments and in modified environments, increasing the vulnerability of populations of the species to certain diseases due to ecological alterations derived from local conservation problems (Orozco et al., 2015). A detailed review by Orozco et al. (2015) looked at pathogens and conditions described in maned wolves, as well as exposures reported through antibody testing in captive and wild specimens, describing the relationship among different pathogens (virus, bacteria and parasites) and the species through published experiences in the management and treatment of these, also making a strong emphasis with the potential pathogen transmission in areas of wild and domestic canid interphase.

Decision-making protocols regarding the management of confiscated wild animals are essential tools within species management plans around the world (Orozco & González-Ciccía, 2015). The aim of these is to serve as a guide where the procedures to be carried out with each specimen are clearly detailed and allow a supported vision of the animal's situation in order to decide its fate efficiently (Orozco & González-Ciccía, 2015; Rodden et al., 2012).

The responsible release of one or more wild animals into nature is a complex process that must be undertaken with great caution, as if sufficient precautions are not taken, the action, instead of being effective for conservation, can be counterproductive and potentially very harmful for the species in question or others of the receiving community (Pautasso, 2009). In that regard, action protocols can be used as models that can provide information from the general to the specific, on the rescue, management and rehabilitation of specimens, based on the experience of professionals from different countries and settings, but also taking into consideration that they have to be adapted to the

specific circumstances of each case (Pautasso, 2009; Rodden et al., 2012; Silva Pinto & Da Silva Pinto, 2014).

The objective of this paper is to describe the clinical process in a case of the rescue, rehabilitation and reintroduction of a specimen of maned wolf (*C. brachyurus*) in Paraguay, presenting all the data obtained during veterinary interventions.

2 | MATERIALS AND METHODS

In October 2020, a juvenile maned wolf, *C. brachyurus*, was rescued in the district of General Bruguez, Department of Presidente Hayes, Paraguay. The animal was in a weakened state, which facilitated its physical restraint. Through a coordinated effort between the local prosecutor's office and the Wildlife Department (DVS – Dirección de Vida Silvestre, in Spanish) of the Ministry of the Environment and Sustainable Development (MADES – Ministerio del Ambiente y Desarrollo Sostenible, in Spanish), the animal was transferred to the city of Mariano Roque Alonso, to a private wildlife centre, on a temporary tenure basis. For the establishment of sanitary check-ups, the health assessment sheets published by Pautasso (2009) were used as a basis.

2.1 | Initial management

The animal, a female, weighing 7 kg, with low body condition, unconscious and unresponsive to stimuli, was admitted to the wildlife centre. Upon clinical inspection, an estimated dehydration of 8% was perceived, as well as watery diarrhoea. A venous access was placed using a 22G catheter in the left cephalic vein, starting the rehydration of the animal with Lactated Ringer's at a rate of 80 mL/kg/day (Kraft, 1999; Sumano López & Ocampo Camberos, 2006), for 3 days. At the same time, a rectal swab was taken for microbial culture.

For the parasite evaluation, serial samples of faeces were taken. Consistent with the copro-parasitological results, intravenous (IV) fluids were accompanied with Metronidazole at a dose of 15 mg/kg (Langlois et al., 2020; Sykes & Papich, 2021), every 12 h, in 4 administrations, as well as Levamisole at a dose of 5 mg/kg (Kraft, 1999), subcutaneously (SC). After 2 days of treatment, the stools became pasty. On the third day, the animal woke up and began drinking water ad libitum. The antimicrobial treatment continued orally (PO) with the administration of sulfamethoxazole–trimethoprim at a dose of 25 mg/kg (Kraft, 1999), every 12 h, for 3 administrations. On 11 October 2020, a combination of praziquantel (50 mg), fenbendazole (500 mg) and pyrantel pamoate (50 mg) was administered PO. Once the animal was stabilised, the first sanitary check-up was coordinated.

2.2 | General considerations

Throughout the 7 months the animal was kept captive, three sanitary check-ups were undertaken. The evaluations performed in each sanitary check-up are meant to get the most information possible from

the individual but were limited by the availability of specific specialists and costs. Due to these constraints only the most important information regarding the current state of the animal was assessed for every check-up. The first sanitary check-up included: blood sampling (haemogram and serum chemistry), serology for antibodies (*Dirofilaria*, Distemper, Brucella, Leptospirosis), faeces (parvovirus and endoparasites), abdominal ultrasound, echocardiogram, dermatologic inspection, peripheral blood cytology, cytology and culture of a sample taken from the affected limb, complete X-ray evaluation, orthopaedic evaluation and biometry. The second sanitary check-up included abdominal and ocular ultrasound, ophthalmologic evaluation, mouth evaluation, dermatologic evaluation, urine sampling, vaginal cytology, specific X-ray of the affected limb, orthopaedic evaluation and biometry. The third sanitary check-up included blood sampling (haemogram and serum chemistry), peripheral blood cytology, serology for antibodies (leptospirosis), faeces (endoparasites) and biometry.

The animal's weight and body measurements followed the guide elaborated by Romero and González (2015) as a reference. Body measurements were taken with a millimeter tape measure, and body weight was taken with a kilogram scale with a 100-g sensibility. For the qualitative description of the faeces, the table elaborated by the National Zoological Park and Smithsonian Institution (2005) was used.

A subcutaneous Global-Ident identification microchip was placed in the interscapular space.

The diet incorporated a variety of food elements, using commercial dog food and chicken parts (wings, thigh, gizzard, heart and liver) as a base, plus vegetables and tubers (*Cucurbita* sp., *Ipomoea batatas*, *Daucus carota sativus*) and fruits (*Malus domestica*, *Pyrus* spp., *Musa* sp., *Mangifera indica*, *Plinia cauliflora*, *Malpighia emarginata*, *Psidium* sp.). Commercial dog food contained approximately 26% protein, 13% fat, 3.5% fibre, 1% (min) to 1.5% (max) calcium and 0.6% (min) to 1.2% phosphorus. Feeding was offered at dusk every day. Mineral supplements (CalciVet B12, Lasca Laboratories, Paraguay), amino acids and vitamins (Tonico Total, John Martin Laboratory, Argentina) were incorporated into the diet.

To stimulate, the exploratory behaviours described by Presa et al. (2015) elements and techniques of environmental enrichment were incorporated. The enrichment sessions were mainly based on changes in the form of food supply, hiding chicken parts under mounds of dry leaves (Figure 1) or inside paper bags, burying cardboard boxes with food, hanging pieces of fruit to a height of 150 cm and offering live prey, such as doves and quails (*Columba livia* and *Coturnix coturnix*) and dead prey (*Mus musculus* and *Rattus rattus*).

The housing of the animal was planned to improve her fitness and exercise her natural behaviours. The enclosure had a total size of approximately 200 m², with a mixed substrate of earth, grass and mounds of dry leaves, as well as a wooden shelter for hiding (Instituto Brasileiro do Meio Ambiente e dos Recursos Naturais Renováveis—IBAMA). As the reintroduction approached, dietary items offered changed progressively to more natural food sources, such as rats and doves, stimulating normal behaviours such as foraging. The tests performed on the animal supported the pre-release health assessment, where body condition was also assessed.



FIGURE 1 Environmental enrichment techniques used in a female maned wolf rescued in Paraguay included hiding the food items.

The management of the animal complied with current national animal welfare legislation, as well as the national wildlife regulations, and was constantly overviewed by DVS-MADES personnel. The transfer of the animal to the private wildlife centre was documented in the Verification Report N° 13/2020 (MADES), and the sampling of the animal was authorised through the Verification Report N° 14/2020 (MADES), which mentioned the need to take samples to establish the animals' health status.

2.3 | Handling and monitoring

The animal was only physically restrained to carry out sanitary check-ups. For this, a snare pole was used, in order to inject the chemical restraint intramuscularly (IM).

In the first and second sanitary check-ups, chemical restraint was performed using a combination of Dexmedetomidine at a dose of 4 $\mu\text{g}/\text{kg}$, Ketamine at a dose of 2 mg/kg and butorphanol at a dose of 0.4 mg/kg, IM. Anaesthetic induction was performed with propofol at a dose of 4 mg/kg IV, and maintenance with isoflurane between 1.5% and 2%. A No. 7 tracheotube was used for intubation. A Ronseda VT200A monitor was used to monitor heart rate and blood pressure (systolic and diastolic), and respiratory rate was monitored visually. Physiologic constants were registered every 5 min.

In the third sanitary check-up, chemical restraint was performed using a combination of Dexmedetomidine at a dose of 4 $\mu\text{g}/\text{kg}$, Ketamine at a dose of 5 mg/kg and Butorphanol at a dose of 0.4 mg/kg, IM. For anaesthetic reversal, Yohimbine was used at a dose of 0.1 mg/kg, IM. Heart rate was monitored using a Littmann Classic III (3M) stethoscope, held against the left side of the thorax, approximately in the fifth intercostal space, and respiratory rate was monitored visually.

2.4 | Haematology and blood chemistry

Blood samples for haematological studies were taken upon admission of the animal, and then during the first and third sanitary check-up. The samples were obtained by the puncture of the cephalic veins of the forearm, through a 21G needle, after antiseptis with cotton soaked in 70% alcohol. The blood samples were deposited in EDTA tubes, and the blood chemistry samples were deposited in tubes without anticoagulant and refrigerated at 4°C until processing.

Blood samples for complete blood count were processed by the following methods. An automatic blood analyser was used to count the figured elements and haemoglobin. The differential leukocyte count and the morphological evaluation of blood cells were performed on a Giemsa stained blood smear. Total plasma protein levels were determined through a refractometer.

The blood samples taken to obtain the biochemical profiles were centrifuged at 3000 rpm (revolutions per minute) for 5 min, to obtain the serum. These were then evaluated by the colourimetric method, carrying out the readings in a spectrophotometer.

2.5 | Serology for infectious diseases

Considering the susceptibilities reported for the species (Orozco et al., 2015; Silva Pinto et al., 2010), as well as the available diagnostic tools, it was established as part of the first sanitary check-up to rule out exposure to *Brucella canis*, *Dirofilaria* spp., *Toxoplasma* spp., *Leptospira* spp., Distemper and Parvovirus. The samples were processed at the Veterinary Diagnostic Center of Paraguay (CEDIVEP).

The qualitative and specific immunochromatographic test was used for the detection of *Brucella* antibodies; immunochromatography for the detection of *Dirofilaria immitis* antigen; immunochromatographic

test for qualitative detection of Distemper viral antigen; qualitative and specific immunochromatographic test for the detection of *Toxoplasma gondii* antibodies; immunochromatographic test for the detection of canine Parvovirus antigen; and microscopic agglutination test for detection of antibodies against *Leptospira* spp. The leptospirosis examination was repeated during the third sanitary check-up.

2.6 | Dermatology

Dermatological inspections were carried out during the first and second sanitary check-ups. Samples for superficial cytology were collected with acetate tape and stained with DiffQuik, for observation under an optical microscope. Trichogram was performed for evaluation of hair, root, stem and tip. Superficial scraping and deep scraping were performed, to determine the presence or absence of mites, placing the samples on a glass slide with immersion oil, and later a cover slide on top, for its observation under an optical microscope.

2.7 | Traumatology and orthopaedics

The orthopaedic examination was performed by the observation of the standing animal, free within the enclosure, and by evaluating videos of the animal. The orthopaedic examination in decubitus was carried out with the animal sedated, evaluating the anatomy of the bones, the muscular conformation and the range of motion of the joints of the four limbs, as described by Aristizabal Escobar (2015).

2.8 | Cytology

Corresponding to the clinical findings in the right forelimb, a fine needle aspirate of the right radioulnar joint was performed using a 21G needle, after antiseptics of the area with 2% chlorhexidine, to determine the cause of the swelling. The aspirated content was distributed on a sterile swab and on a glass slide. The swab was placed in Stuart transport medium and refrigerated at 4°C until cultured. The material placed on the slide was stained with Giemsa.

During the first and third sanitary check-ups, samples were taken for the detection of haemoparasites. During the first sanitary check-up, a 21G fine-needle aspirate of bone marrow was performed, as well as a peripheral blood smear, using Giemsa staining. During the third sanitary check-up, a peripheral blood smear was performed.

During the second sanitary check-up, a vaginal swab sample was taken to perform vaginal cytology. A sterile swab was rubbed against the vaginal mucosa, and then it was taken to a glass slide where the smear was made. Once the sample was dry, it was fixed with methanol and stained with Giemsa, for observation under the microscope.

2.9 | Urine

During the second sanitary check-up, a urine sample was taken by ultrasound-guided puncture with a 21G needle. The urine sample was sent, in a sterile cup, to the Veterinary Diagnostic Center of Paraguay (CEDIVEP) for routine urinalysis.

2.10 | Ophthalmology

During the second sanitary check-up, the ophthalmological evaluation of both eyes was performed. The ocular examination, including the neuro-ophthalmic, lacrimal system and adnexal evaluation, was performed according to the diagnostic sequence described by Featherstone and Heinrich (2013). A Tono-pen VET device was used to assess intraocular pressure (IOP).

2.11 | Mouth assessment

The oral assessment was performed during the second sanitary check-up. The mouth was opened so that the states of the mucous membranes and the tongue were evaluated. During the dental inspection, the teeth were counted, verifying the quantity according to the data of the species, recording the presence of deciduous pieces, and their condition was observed, assessing the presence or absence of fractures. The characteristics of the enamel were evaluated, as well as the colouration of the gums, ruling out inflammations. The probing was carried out using a millimeter periodontal probe, inserting the tip between the gum and the tooth, covering all the faces of each tooth and recording the depth of the periodontal pockets. X-rays were taken with REMEX-T100 equipment, with a Sopix Size 1 sensor, using 70 kV, and 2 mA in 0.03 s.

2.12 | Ultrasound

The ultrasound review was performed during the first and second sanitary check-ups. The ultrasound equipment used was a General Electric Logiq E R7, with linear probes (L4 - 12T) (L10 - 22) and microconvex (8C), multi-frequency, between 8-13 and 10-22 MHz. Before the study, the hair in the abdominal region was shaved with a No. 40 blade, as well as the use of coupling gel.

Abdominal ultrasound evaluated the topography, shape, margins, echotexture and echogenicity of the abdominal organs (liver, gallbladder, kidneys, spleen, pancreas, gastrointestinal tract, adrenal glands, bladder and gonads), as well as ocular B-mode ultrasound evaluation, measuring the eyeballs and differentiating the internal architecture of them.

During the first sanitary check-up, echocardiography was performed. The equipment used for echocardiography was a Mindray M7 premium with an 8-5 MHz phased array transducer.

2.13 | X-rays

Radiographic studies were performed during the first and second sanitary check-ups. The X-ray equipment used was a GIERTH HF 80, with a DRGEM Mano4343W detector panel, using 78 kW and 0.03 mA/s. During the first sanitary check-up, simple X-rays of the thorax, thoracolumbar spine, pelvis and wrists of the right thoracic limb were taken in orthogonal projections. During the second sanitary check-up, radiographs of the carpal bones, metacarpals and phalanges of the right thoracic limb were taken in orthogonal projections.

2.14 | Copro-parasitology

Serial fresh faecal samples were obtained on days 1 (02 October), 4 (05 October), 6 (07 October), 8 (09 October), 14 (15 October) and 20 (21 October) from the reception of the animal. The samples were collected from the environment immediately after defecation and kept in sterile vials at a temperature of 4°C until processing.

The samples were processed with the following techniques: centrifugal-flotation technique in sodium chloride (Pereckiene et al., 2007), Hoffman sedimentation (Hoffman et al., 1934), 10% formalin (Villalobos et al., 2015) and McMaster (Zajac et al., 2021).

3 | RESULTS

3.1 | General management

Upon entry of the patient, a rectal swab was taken and sent to the Veterinary Diagnostic Center of Paraguay (CEDIVEP) for microbiological diagnosis, where no bacterial growth was reported. On fresh examination, 1–2 leukocytes were observed per field, and no red blood cells were observed.

The records of the individual's weight and body measurements are presented in Table 1.

Throughout the study period, the individual maintained an elusive and distrustful character. Attachment to humans was not perceived, so there was no problem associated with human contact that could hinder a response to rewild the individual (Groggan & Kelly, 2016). Through the provision of live prey, self-sufficiency to search for food was evaluated, as well as search and hunting behaviour, also considering the positive impact that environmental enrichment can have on animal welfare during captivity, and the probabilities of subsequent successful reintroduction to its habitat (Mendes et al., 2011, 2016). The individual maintained a selective appetite throughout the study period, preferring animal-based food and sweet fruits such as apples and mango (*M. domestica*, *M. indica*) over some other fruits and tubers, constantly leaving pieces of pears (*Pyrus* spp.), sweet potato (*I. batatas*) and carrot (*D. carota sativus*) half-eaten.

TABLE 1 Weight and body measurements taken during three sanitary check-ups from a female maned wolf rescued in Paraguay in 2020–2021.

Value	18/10/20	24/11/20	10/04/21
Approximate age (months)	5	6	11
Weight (kg)	7	10.5	18
Total length (1 + 2) ^a (cm)	101	119	138
Head length + body (1) ^a (cm)	71	79	95
Length of the tail (2) ^a (cm)	30	40	43
Length of the right ear (A) ^a (cm)	13.5	14	16
Width of right ear (B) ^a (cm)	7	8	9
Length of head (C) ^a (cm)	20	25	24
Chest circumference (4) ^a (cm)	40	45	51
Height (5) ^a (cm)	ND	68	ND
Neck circumference (6) ^a (cm)	22	26	33
Head width (D) ^a (cm)	14	13	ND
Length of right arm (cm)	60	63	61
Length of right hand (cm)	ND	19	18
Length of right leg (cm)	ND	63	71
Length of right foot (cm)	ND	25	27

Abbreviation: ND, no data.

^aUse Romero and González (2015) for reference.

TABLE 2 Haematological values obtained on three occasions from female maned wolf rescued in Paraguay in 2020–2021, compared with reports from other authors.

VALUE	5/10/20	18/10/20	10/4/21	Orozco et al (2015)	May-Junior et al (2009)	Teare (2012)
Haemoglobin (g/dL)	9.8	13.3	15.0	14.7 ± 2.7	12.2 ± 0.4	13.6 ± 2.3
Haematocrit (%)	29	47	53	46.0 ± 6.7	38.7 ± 1.0	40.9 ± 6.5
Erythrocytes (mill/mm ³)	4.2	5.5	7.2	6.5 ± 1.6	4.7 ± 0.1	5.43 ± 0.95
Leukocytes (10 ³ /mm ³)	5.6	14.7	12.1	9.4 ± 3.3	12.3 ± 0.9	10.36 ± 4
Platelets (mm ³)	320.000	150.000	150.000	ND	ND	219.000
Banded neutrophils (mm ³)	168	0	0	ND	ND	419 ± 834
Segmented neutrophils (mm ³)	2856	9261	9075	64.0 ± 14.6 (%)	7300	7296 ± 3251
Lymphocytes (mm ³)	2352	4785	2178	26.3 ± 13.8 (%)	3400	2150 ± 1115
Monocytes (mm ³)	0	213	363	4.0 ± 5.4 (%)	600	333 ± 280
Eosinophils (mm ³)	224	441	484	4.9 ± 5.9 (%)	900	662 ± 454
Basophils (mm ³)	0	0	0	0.0 ± 0.2 (%)	10	109 ± 119
MCV (fL)	69	85	73	98.9 ± 24.1	82.1 ± 1.4	75.3 ± 7.4
MCH (pg)	23.3	24	21	28.2 ± 7.9	26.1 ± 0.5	25.5 ± 2.4
MCHC (g/dL)	33.8	28	28	28.3 ± 3.6	31.6 ± 0.5	33.5 ± 2.4
Total solids (g/dL)	5.97	8.0	8.3	6.7 ± 1.0	7.6 ± 0.3	6.2 ± 0.8

Abbreviation: ND, no data.

3.2 | Restraint and monitoring

For the first and second sanitary check-ups, the anaesthetics were administered IM. Five minutes after first administration, the animal was found in anaesthetic plane. The first sanitary check-up took 94 min, and the second took 50 min. As the maintenance was performed with isoflurane, there is no information as to the duration of the anaesthetic protocols effect. For the third sanitary check-up, time from administration to complete effect of anaesthetics was 6 min. Yohimbine was administered 30 min later, and the animal was beginning to stand up 8 min after administration (38 min after administration of anaesthetics).

The heart rate during the three sanitary check-ups ranged between 86 and 107 beats per minute, with a systolic pressure between 70 and 110 mm Hg and diastolic pressure between 37 and 80 mm Hg. The respiratory rate ranged between 13 and 19 breaths per minute, and the body temperature between 36.9 and 37.6°C.

3.3 | Haematology and blood chemistry

Table 2 shows the haematological values obtained from the animal by date, compared to the average results and standard deviation obtained in works carried out in Argentina (Orozco et al., 2015), Brazil (May-Junior et al., 2009) and the United States of America (Teare, 2012). The work carried out by Orozco et al. (2015) compiled the data on captive animals kept in various institutions in Argentina. The report by May-Junior et al. (2009) in Brazil describes samples taken from specimen inside a national park and compared them to samples taken from ani-

mals on the boundaries or on adjacent farmlands. The work by Teare (2012) compiles data obtained from 27 institutions in the International Species Information System database.

The first haemogram showed polychromatophilic erythrocytes, anisocytosis (+), poikilocytosis, dacryocytes (+), codocytes (+), acanthocytes (+) and coin pile formation (+). The white blood cells showed normal morphology. In the second haemogram, performed during the first sanitary protocol, the red blood cells showed anisocytosis and poikilocytosis. The white blood cells showed no particularities. In the haemogram performed during the third sanitary protocol, the red blood cells and white blood cells were normal.

Table 3 presents the results obtained from blood chemistry, in comparison to the average results and standard deviation obtained by Orozco et al (2015), May-Junior et al. (2009) and Teare (2012).

3.4 | Serology for infectious diseases

The results shown in Tables 4 and 5 were obtained.

3.5 | Dermatology

Dermatological inspections were performed during the first and second sanitary check-ups. No skin alterations were found during the first sanitary check-up. Apparently, normal epithelial cells were observed. No fungal spores or mites were observed in the scraping.

During the second sanitary check-up, cytology with acetate tape, trichogram and scraping were performed, and no particularities were reported.

TABLE 3 Blood chemistry values obtained during two sanitary check-ups from a female maned wolf rescued in Paraguay in 2020–2021.

Analyte	18/10/20	10/4/21	Orozco et al (2015)	May-Junior et al (2009)	Teare (2012)
Creatinine (mg/100 mL)	2.7	3.0	1.4 ± 0.4	1.0 ± 0.1	1.3 ± 0.4
Urea (mg/100 mL)	57	63	57.3 ± 19.1	59.5 ± 12.6	ND
ALT/GPT (IU/L)	91	72	56.0 ± 54.4	47.2 ± 8.7	78 ± 72
Albumin (g/dL)	2.0	2.3	3.3 ± 0.5	2.6 ± 0.1	3.0 ± 0.4
Alkaline phosphatase (IU/L)	398	371	75.2 ± 95.9	ND	137 ± 191

Abbreviations: ALT, alanine aminotransferase; ND, no data.

TABLE 4 Tests performed to rule out the presence of the most common pathogens in a female maned wolf rescued in Paraguay in 2020–2021.

Pathology	Method	Result
Canine brucellosis	Qualitative and specific immunochromatographic test for the detection of <i>Brucella</i> antibodies	Negative
Dirofilariosis	Immunochromatography for the detection of <i>Dirofilaria immitis</i> antigen	Negative
Distemper	Immunochromatographic test for qualitative detection of distemper viral antigen	Negative
Toxoplasmosis	Qualitative and specific immunochromatographic test for the detection of <i>Toxoplasma gondii</i> antibodies	Negative
Parvovirus	Immunochromatographic test for the detection of canine Parvovirus antigen	Negative

TABLE 5 Tests for antibodies against *Leptospira interrogans* serovars, performed during two sanitary check-ups, in a female maned wolf rescued in Paraguay in 2020–2021.

<i>Leptospira</i>	Method	18/10/20	10/4/21
<i>Grippityphosa</i>	Microscopic agglutination test (MAT)	+1/50	+1/200
<i>Tarasovi</i>		N	N
<i>Hardjo</i>		N	N
<i>Pyrogenes</i>		N	N
<i>Wolffi</i>		+1/200	N
<i>Canicola</i>		N	N
<i>Pomona</i>		N	+1/50
<i>Ictero</i>		+1/50	N

Abbreviation: N, negative.

3.6 | Traumatology and orthopaedics

In the first orthopaedic evaluation, an abnormal weight distribution was observed, with lameness of the right forelimb (grade 3), valgus deviation of the limb, with the presence of muscle atrophy being noticeable from a distance. Once sedated, the limb was observed more closely, finding a bulge in the distal right radius/ulna and carpus, crepitation of the area was perceived through palpation, compatible with a solution of continuity of bone, the diameter of the limb measured in the middle third of the arm was 20.5 cm, while on the healthy side of 23 cm. Sensitivity was not evaluated because the patient was sedated.

In the second evaluation, the animal continued with an abnormal weight distribution, but less pronounced, and presented lameness

(grade 2), and slight valgus deviation of the limb. Once sedated, the bulging of the distal right radius and ulna and carpus was evaluated, which was already without local crepitus, compatible with a fracture in the process of resolution (bone callus). Sensitivity was not evaluated because the patient was sedated.

3.7 | Cytology

Considering the radiological findings in the right radius and ulna during the first sanitary check-up, a 21G fine needle aspirate was performed for cytological study. Using routine Giemsa staining of the smear, moderate cellularity was observed, composed mainly of a

population of degenerated and some reactive neutrophils, macrophages with foamy-vacuolated cytoplasm, osteoblasts and osteoclasts. Within the sparse macrophages and neutrophils, colonies of bacillary bacteria were observed sometimes smaller in length, approximately 0.5 μm wide and 2–3 μm long. The findings were suggestive of suppurative osteomyelitis associated with intralesional bacillary bacterial colonies.

The cytology findings coincided with the microbial culture performed on the aspirate, which isolated gram-negative non-lactose-fermenting bacilli. The antibiogram result was indicative of sensitivity to cefepime, tetracycline, sulfatrimethoprim, amikacin, ertapenem, ceftazidime, amoxicillin, cefotaxime, ceftriaxone and gentamicin; and slight sensitivity to ciprofloxacin. Antibiotic treatment was performed with applications of long-acting amoxicillin (amoxicillin trihydrate) at a dose of 22 mg/kg SC, every 48 h, for five applications.

During the first sanitary check-up, a 21G fine needle aspirate of bone marrow and a peripheral blood smear were performed. No haemoparasites were identified. During the third sanitary check-up, a peripheral blood smear was performed. No cells containing corpuscles compatible with haemoparasites were observed.

During the second sanitary check-up, a swab was performed for vaginal cytology. Cells compatible with proestrus stage were observed.

3.8 | Urine

The results are shown in Table 6.

3.9 | Ophthalmology

During the second sanitary check-up, an ophthalmologic evaluation of both eyes was performed, which were found to be unaltered, with good optical functionality.

In both eyes, an IOP of 18 mm Hg was recorded using a Tono-pen VET device, and a Schirmer's test result of 17 mm/min. Positive direct and consensual reflexes were present.

The eyelids were unremarkable. The lacrimal ducts presented a positive Jones test. The conjunctivae were free of congestion and secretions. The corneas were transparent and bright, negative for Rose Bengal.

On inspection of the anterior chambers and drainage angles, pupils, iris and crystalline lens, no particularities were observed. On fundus inspection, normal vascularisation was perceived, with no particularities.

3.10 | Mouth assessment

During the second sanitary check-up, a dental evaluation was performed. At the time of the evaluation, the animal had all of its permanent teeth erupted in its mouth, and no dental fractures were described.

TABLE 6 Urinalysis results obtained from a female maned wolf rescued in Paraguay in 2020–2021.

Test	Results
Urine	
Colour	Yellow
Aspect	Clean
Density	1.030
PH	7
Chemical exam	
Proteins	30 mg/dL
Glucose	Not detectable
Ketones	Not detectable
Bilirubin	Not detectable
Urobilinogen	Not detectable
Nitrites	Negative
Leukocyte esterase	Not detectable
Blood	Not detectable
Haemoglobin	Not detectable
Microscopic examination	
Leukocytes	Not observed
Red blood cells	2–3 per field
Epithelial flat cells	3–5 per field
Bilirubin crystals	Low quantity

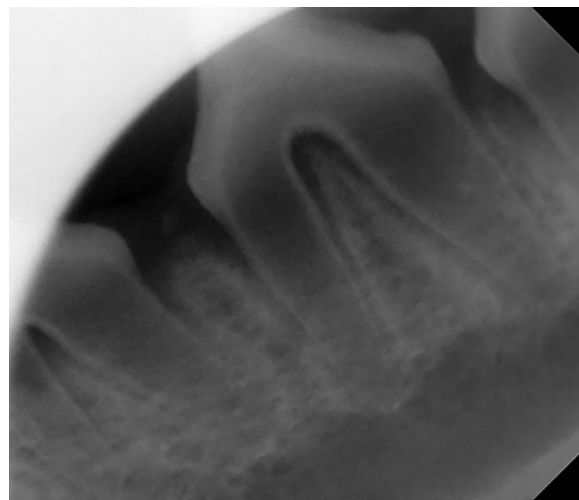


FIGURE 2 X-ray of lower premolar in a female maned wolf rescued in Paraguay in 2020–2021.

Tooth 101 (right upper first incisor), 201 (left upper first incisor), 202 (left upper second incisor), 301 (left lower first incisor) and 401 (right lower first incisor) showed enamel hypoplasia.

When periodontal probing was performed on all her teeth, no periodontal pockets were detected, the gingiva was pink in colour, and there was no gingivitis.

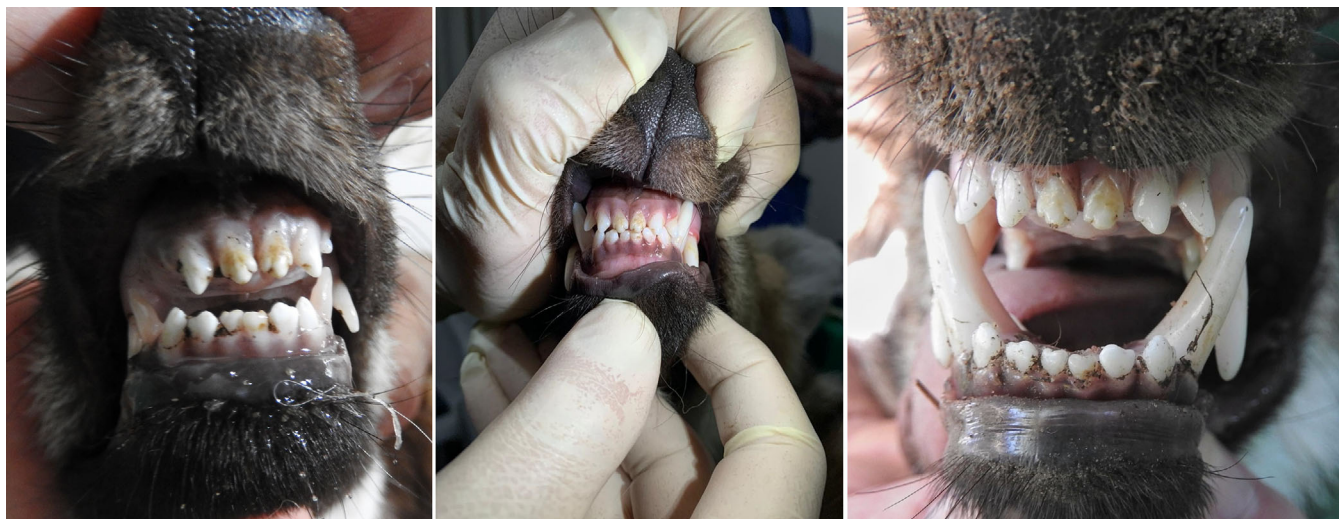

FIGURE 3 Teeth during the first (left), second (middle) and third sanitary check-up (right) in a female maned wolf rescued in Paraguay in 2020–2021.

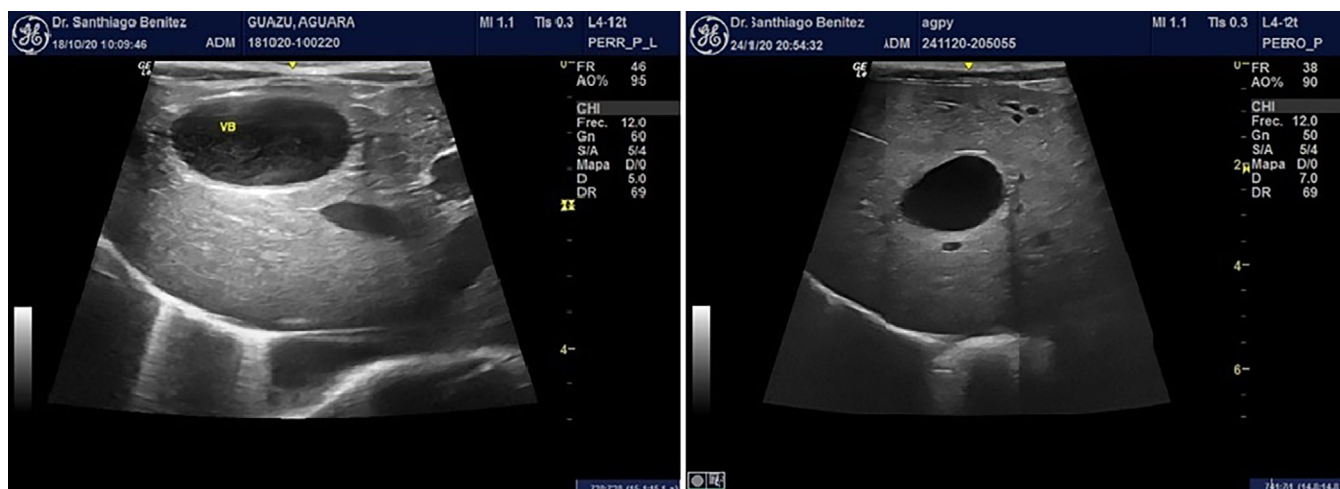


FIGURE 4 Ultrasound assessment of gallbladder of a female maned wolf rescued in Paraguay in 2020–2021, during first (left) and second (right) sanitary check-up.

Radiographic images were taken with REMEX-T100 equipment, with a Sopix Size 1 sensor, using 70 kV, and 2 mA in 0.03 s. The study shows the lower premolar with a large pulp chamber and an open apex (Figure 2).

Figure 3 shows a comparison of the evolution of the teeth between 18 October 2020, 24 November 2020 and 10 April 2021.

3.11 | Ultrasound

During the first sanitary check-up, the gallbladder presented a wall thickness of approximately 0.14 cm, with a scarce quantity of fine cellularity suspended in its interior, and a volume of 5 mL (Figure 4). The stomach (Figure 5) presented a wall thickness of 0.4 cm in

the ventral portion, and 0.39 cm in the dorsal portion. Stratification of differentiated layers was observed with increased echogenicity in its mucosal and muscular layer, associated with inflammatory process.

In intestinal loops, slow motility was recorded in thin loops with differentiated stratification and mucous pattern, with mostly mucous/pasty content in transit (Figure 6). The duodenum presented parietal thickness of approximately 0.34 cm in the area of evaluation. The jejunum presented parietal thickness of approximately 0.24 cm. The ascending portion of the evaluated colon presented a distension of 0.9 cm with a wall thickness of 0.24 cm and in its descending portion, distension of 1.57 cm approximately and parietal thickness of 0.4 cm, irregular wall surface. Throughout its transit, there was evidence of mucous-paste-like content. The diagnostic impression was

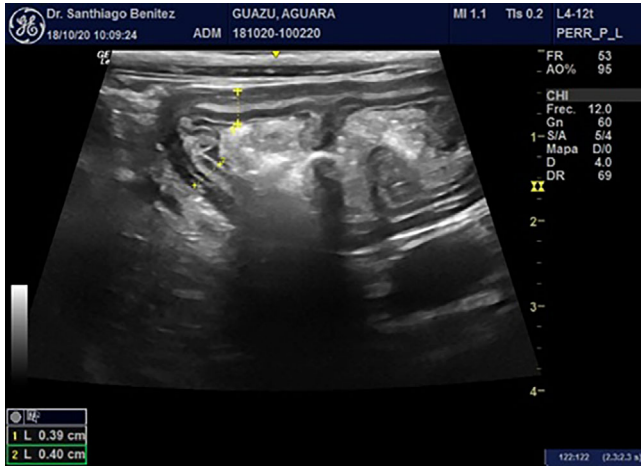


FIGURE 5 Ultrasound assessment of stomach in its parietal measurement, both dorsal and ventral, during the first sanitary check-up of a female maned wolf rescued in Paraguay in 2020–2021.

of an intestinal inflammatory process (enterocolitis). No structures suggestive of foreign bodies were evidenced in gastrointestinal transit.

Free fluid in the abdominal cavity was also reported in small quantity, which could be associated to physiological findings in domestic canine puppies, not ruling out possible inflammatory fluid at the time of the study. The rest of the abdominal organs evaluated (liver, spleen, kidneys, adrenal, pancreas, bladder, uterus and ovaries) were apparently preserved.

At the second sanitary check-up, compared to the previous study, the gallbladder presented wall thickness of approximately 0.11 cm, anecogenic content of clean appearance in its interior, volume of approximately 1.99 mL (Figure 4). The stomach was empty, with a cartwheel appearance, and a wall thickness of approximately 0.4 cm in the ventral area, with preserved stratification. Intestinal loops

with expected peristalsis and mucous-gas content in transit, parietal duodenal thickness of 0.36 cm and jejunum of 0.27 cm approximately, colon presented parietal thickness of 0.14 cm approximately in descending portion with hyperechoic interfaces with posterior acoustic shadow indicating the presence of apparent solid faecal matter and gas (Figure 6).

An ocular ultrasound study was also performed (Figure 7), reporting both eyeballs with an axial dimension of 1.7 cm. Anterior chamber, crystalline lens and vitreous chamber were preserved. Retro bulbar space and optic nerve were preserved.

During cardiac examination, no audible murmur or gallop was evidenced, and a normal pulse was present. The findings of the two-dimensional echocardiography are presented in Table 7.

Echocardiography/Doppler study showed preserved mitral, tricuspid and aortic valve flows, turbulent pulmonary valvular flow, suggestive of mild valvular insufficiency.

3.12 | X-rays

During the first sanitary check-up, plain radiographs of the thorax, thoracolumbar spine, pelvis and carpus of the right thoracic limb, obtained in orthogonal projections, were taken. Bronchial pulmonary pattern was observed (Figures 8 and 9); as were a fracture in the distal third of the right radius and ulna in the process of bone repair with swelling of adjacent soft tissues (Figure 10); and dilatation of the intestinal segment (Figure 11) matching the ultrasound finding of ileus.

During the second sanitary check-up, X-rays were taken of the carpal bones, metacarpals and phalanges of the right thoracic limb obtained in orthogonal projections. Compared to the first study performed, fracture reduction was observed in the right radius and ulna (Figure 12), and no changes suggestive of osteomyelitis were observed (Figure 13).

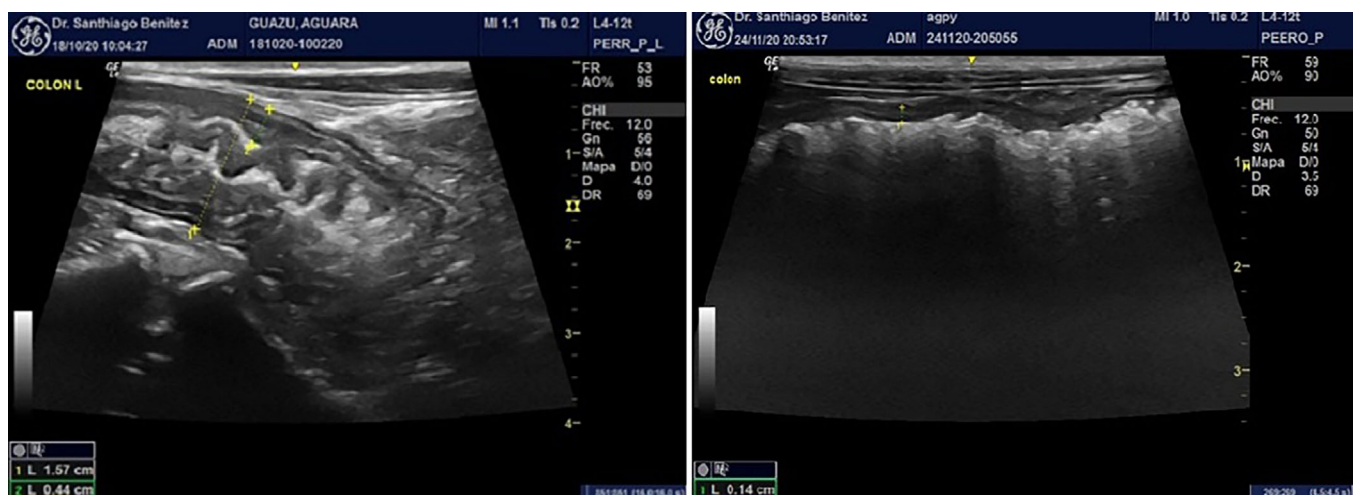


FIGURE 6 Ultrasound assessment of descending colon of a female maned wolf rescued in Paraguay in 2020–2021 in longitudinal section: during the first sanitary check-up, with marked wall thickening and mucosal pattern with wall irregularity (left), and during the second sanitary check-up, with preserved wall, regular surface, solid stool pattern and gas in transit (right).

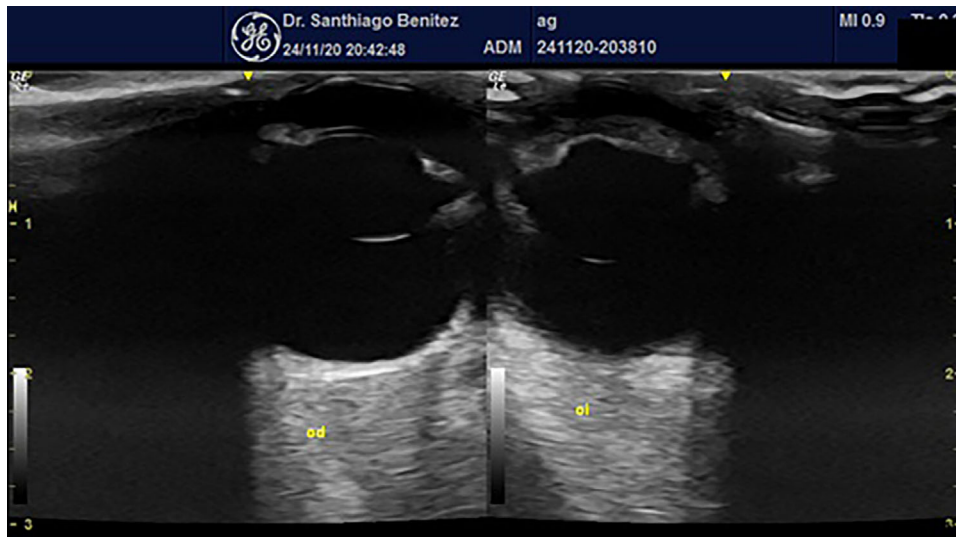


FIGURE 7 Ultrasound assessment of both eyeballs in dual function, in a female maned wolf rescued in Paraguay in 2020–2021.

TABLE 7 Echocardiographic findings from a female maned wolf rescued in Paraguay in 2020–2021.

Two-dimensional echocardiography							
LA	15.7 mm	LVSD	6.8 mm	LVSS	6.8 mm	EF%	61.1
AO	14.3 mm	LVDd	25.8 mm	LVDs	17.8 mm	SF%	31.1
LA/AO	1 mm	PLVWd	5.5 mm	PLVWs	7.2 mm		

Abbreviations: AI/AO, atrium aorta relation; AO, aorta; EF%, left ventricular ejection fraction; LA, left atrium; LVDs, cavity in left ventricular systole; LVDd, cavity in diastole of the left ventricle; LVSD, septal wall in diastole of the left ventricle; PLVWd, free wall in left ventricular diastole; PLVWs, free wall in left ventricular systole; LVSS, septal wall during left ventricular systole; SF%, shortening fraction.

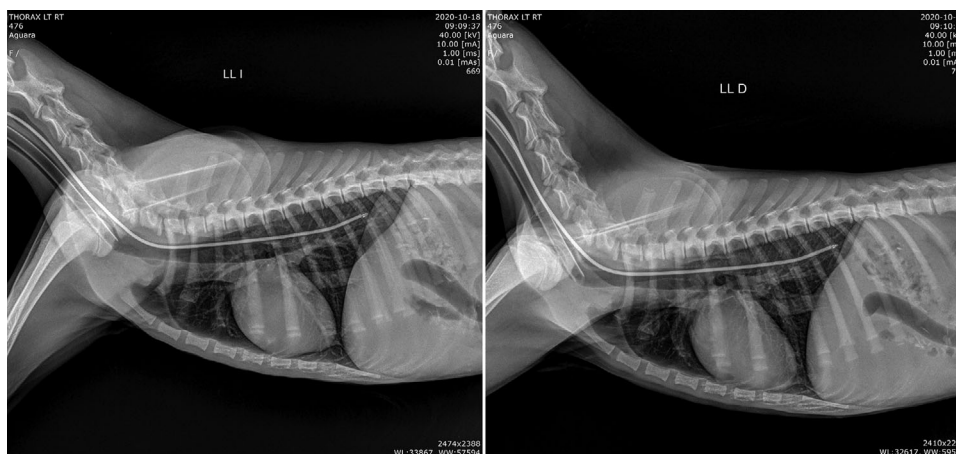


FIGURE 8 Increased pulmonary radiodensity of bronchial pattern in a female maned wolf rescued in Paraguay in 2020–2021, during the first sanitary check-up. Left latero-lateral projection (left) and right latero-lateral projection (right). Presence of tracheal tube and oesophageal tube.

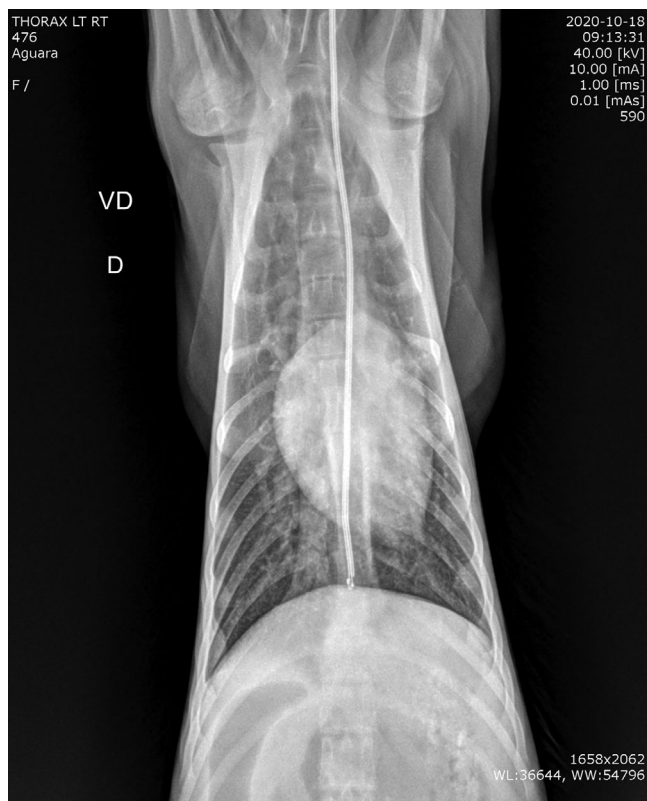


FIGURE 9 Increased pulmonary radiodensity of bronchial pattern in a female maned wolf rescued in Paraguay in 2020–2021, during the first sanitary check-up. Ventro-dorsal projection. Presence of tracheal tube and oesophageal tube.

3.13 | Copro-parasitology

The findings are shown in Table 8.

The results expressed in Table 8 correspond with the initial treatment with metronidazole, levamisole and sulfamethoxazole–trimethoprim during the first 4 days, in addition to the administration of praziquantel, fenbendazole and pyrantel pamoate on 11 October 2020, in the gradual reduction of the parasite load.

3.14 | Relocation and reintroduction

The management was not modified in the days prior to the transfer. The day before the transfer, the animal was fed normally, at sunset. On the day of the transfer, the animal was placed in a wooden transport box with guillotine-style doors at both ends, with hay substrate. The embarkation took place hours before dawn, and the release was made around noon. During the transport of the animal to the release site, there were no particularities. The animal was calm inside the transport box, being found lying down during each observation (every 60 min).

The reintroduction site was on the same property where the animal was found, as suggested by Groggan and Kelly (2016), but further away from the cattle pastures. The transport box was moved to the release site, placed on safe ground, opening the front door first, with-

out the animal getting out of it. When the back door was opened, the animal quickly exited, moving approximately 20 m away, and stopping to observe the crowd from the vegetation (Figure 14). After 15 s, it moved away at a relaxed pace, moving deeper into the vegetation until it disappeared from sight.

Radio tracking of the individual was considered first but could not be done for financial reasons. Camera traps were installed in the surroundings, and captures of maned wolves were registered, but the animal had no gross distinguishable feature that allowed identification. Work was carried out with people living near the release site, specifically educating the population about the species, its role in the environment, and the low risk to humans of coexisting with the species.

4 | DISCUSSION

4.1 | General considerations (management)

At the moment the animal was released, it had reached the range of weight expected for the species, between 18 and 32 kg (Padilla & Hilton, 2015), and although it matches the lower end of the weight range, this was considered appropriate, as the specimen was a young adult. Regarding the growth (Table 1), the results were consistent in that the period of rapid growth had passed and limbs were growing at a slower rate, and these were yet to reach the average length, which happens after 1 year of age (Brady & Ditton, 1979; Wayne, 1986), although limb development could also have been hindered by pathologic processes such as parasitic diarrhoea, captivity-related stress and incomplete diet (AZA Canid Taxon Advisory Group, 2012). The body average body and tail length at the last check-up match that reported by Dietz (1985).

Enclosure management, such as cleaning and installing enrichment opportunities, was done during the day, as the species is generally more active at night than during the day (Dietz, 1984), and the animal was usually found hiding. As the species is considered a generalist omnivore, the diet was prepared considering that, according to several studies through different biomes, almost half of the food items are of animal origin, and the other half is plant material (Aragona & Setz, 2001; Bueno et al., 2002; Bueno & Motta-Junior, 2006; Diets, 1984; Massara et al., 2012; Motta-Junior et al., 1996; Queirolo & Motta-Junior, 2007; Santos et al., 2003), which in this case had a good acceptance, although a preference to animal origin items was perceived. Preparing a diet in captivity is complex, not only due to the challenge of imitating the wide variety of food items that the species consumes in the wild, but also because the feeding ecology has to be studied, so that the feeding behaviour is kept and stimulated (Rodden et al., 2012). The species is not considered a predator of large animals, and they consume a wide variety of invertebrates, fruits and shrubs, so the food offered should consist of a nutritionally complete dry dog food, supplemented with fruits, vegetables and whole prey items such as small rodents, quail or chicks (Rodden et al., 2012). Incorporating live and thawed animals of controlled origin, such as doves and rats, helped by stimulating the feeding behaviour, and the choice of commercial

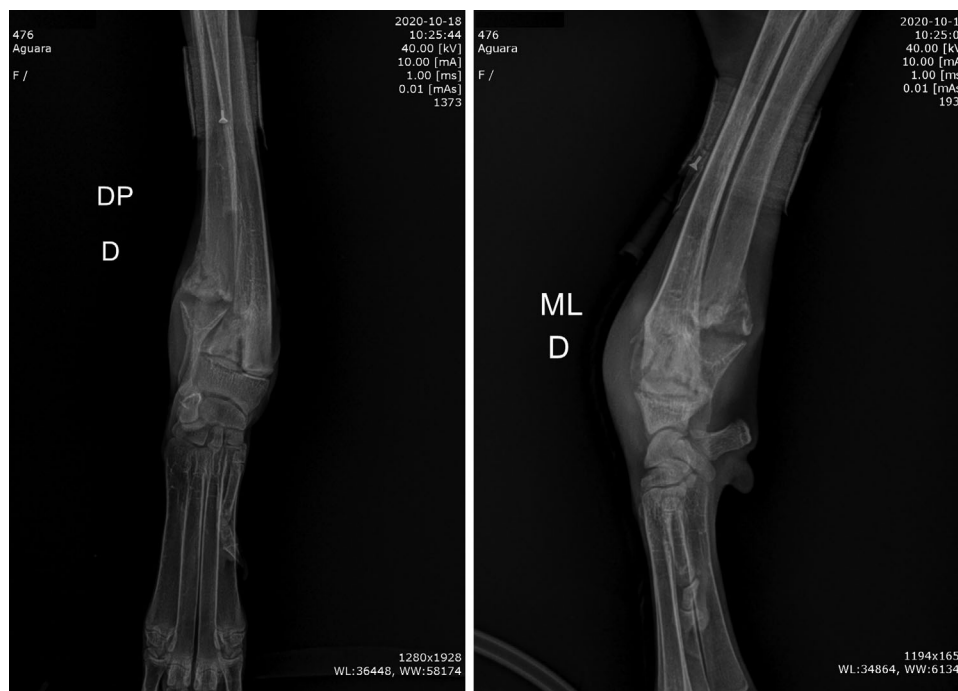


FIGURE 10 Fracture in the distal third of the right radius and ulna in a female maned wolf rescued in Paraguay in 2020–2021, during the first sanitary check-up. Anteroposterior view (left) and medio-lateral view (right).

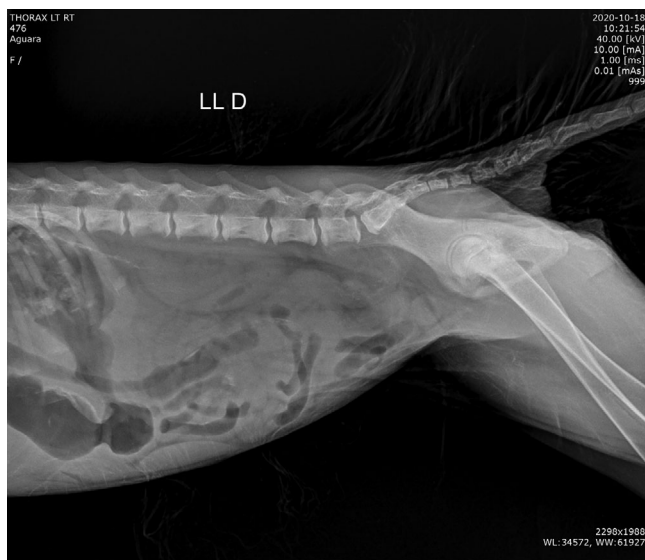


FIGURE 11 Right latero-lateral projection of the lumbar spine in a female maned wolf rescued in Paraguay in 2020–2021, showing an intestinal segment with gas dilatation in the mesogastrium during the first sanitary check-up.

dog food that was incorporated to the diet was directly related to the quality of the food and the nutritional requirements of maned wolves which, compared to other canids, are lower in protein intake (Barboza et al., 1994). In regard to the presentation of the food, when chicken items were offered, a positive response was seen when hiding and burying the food items, in the sense that it stimulated an interaction between the animal and her enclosure.

Through environmental or behavioural enrichments, the animal is provided with a variety of stimuli that can increase physical activity, stimulate cognition and promote natural behaviours (Rodden et al., 2012), which elicit positive effects on the behaviour of captive maned wolves (Cummings et al., 2007). Several enrichment strategies can be applied to promote foraging, feeding, object manipulation and investigation, such as olfactory enrichment (herbs and spices, animal scents, faeces or urine from other species) and physical objects (Cummings et al., 2007; Rodden et al., 2012), although providing the animal with the ability to forage for food, through food scattering, is apparently a more effective enrichment strategy that introducing objects (Cummings et al., 2007; Vasconcellos et al., 2009), and has also shown to reduce stress (Coelho et al., 2016). Response to foraging stimuli will also help assess the animals' behaviour when considering reintroduction (Coelho et al., 2011).

4.2 | Handling and monitoring

Considering the extreme heatwaves in Paraguay (Rivera et al., 2022), before any capture is planned, ambient temperature and humidity have to be considered, and the procedure should be discontinued at any time the health of the animal is in question (Rodden et al., 2012). In this case, snare pole was used as it allowed a quick grasp of the animal while keeping the handler at a safe distance from the mouth and allowing the veterinarian safe access to the hindlimbs, to inject the induction drugs, and quickly releasing the animal afterwards. Care has to be taken not to choke the animal or produce chronic damage on the neck tissues while using the snare pole, so an experienced handler is

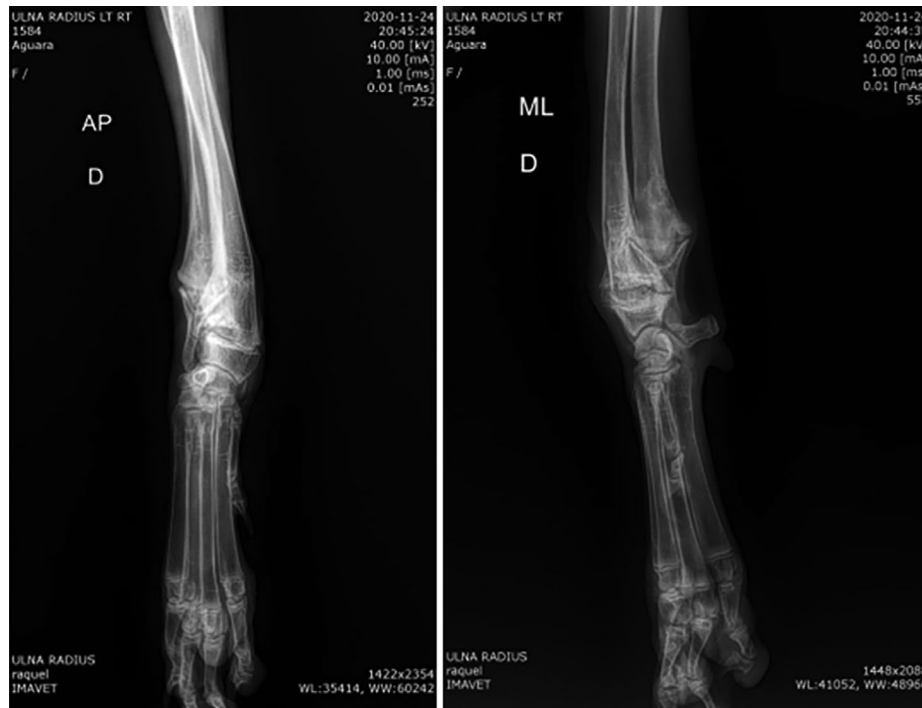

FIGURE 12 Apparent valgus deviation of distal radius and ulna, at joint transition, anterior–posterior view (left); and discrete fracture line in distal diaphysis of the right radius and ulna, medio-lateral view (right), during the second sanitary check-up in a female maned wolf rescued in Paraguay in 2020–2021.

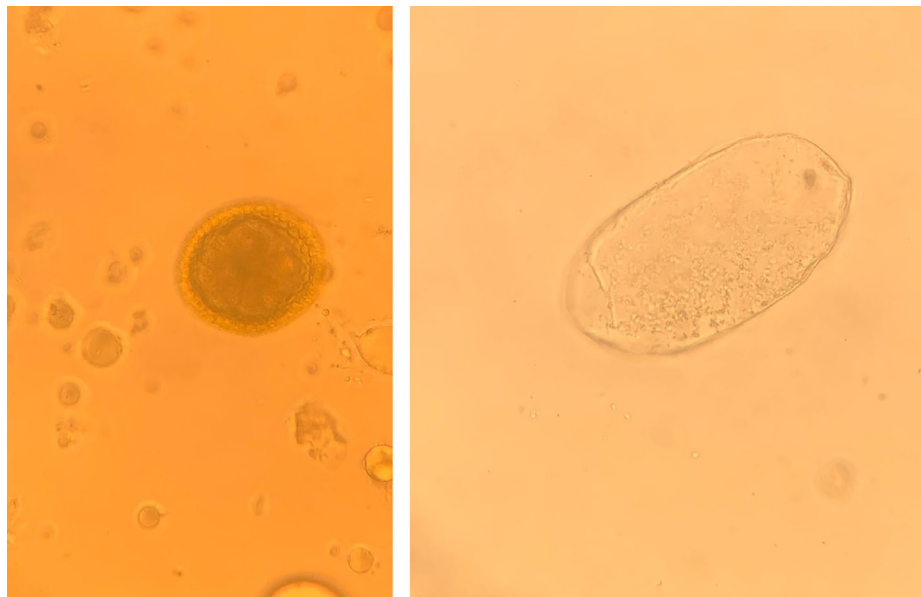


FIGURE 13 Egg compatible with *Lagochilascaris* sp. (left) and *Balantidium* sp. (right) from a female maned wolf rescued in Paraguay in 2020–2021.

preferred. Catch box, catch nets and crowding boards are other methods used for physical restraint in this species, plus chemical restraint for any procedure (Maned Wolf Species Survival Plan [MWSSP], 2007).

In this case, the drugs administered have already been used successfully in various reports, and the animal was constrained in an enclosure, which aided in the handling as the space was limited and the animal could be cornered, but different drug combinations and doses

TABLE 8 Results of the copro-parasitological studies from a female maned wolf rescued in Paraguay in 2020–2021.

Sample date	Flotation centrifuge	Sedimentation	Formalin	McMaster
02–10	<i>Lagochilascaris</i> sp. (Figure 13)	<i>Balantidium coli</i> (Figure 13)	<i>Lagochilascaris</i> sp., <i>Balantidium coli</i>	500 epg <i>Lagochilascaris</i> sp.
05–10	<i>Lagochilascaris</i> sp.	N	<i>Balantidium coli</i>	300 epg <i>Lagochilascaris</i> sp.
07–10	<i>Lagochilascaris</i> sp.	<i>Balantidium coli</i>	<i>Lagochilascaris</i> sp., <i>Balantidium coli</i>	200 epg <i>Lagochilascaris</i> sp.
09–10	N	<i>Balantidium coli</i>	<i>Balantidium coli</i>	N
15–10	N	N	<i>Lagochilascaris</i> sp., <i>Balantidium coli</i>	N
21–10	N	N	N	N

Abbreviation: N, no findings.

have been reported for immobilisation and anaesthesia in the species, depending on availability, particular situations such as wild versus captive situations, factors such as age and health, and the experience of the veterinarian (Alves et al., 2023; Bronson et al., 2021; Furtado et al., 2006; Rodden et al., 2012). Induction times in this case matched the reported range, between 3 and 15 min. Reported heart rates range between 60 and 192 beats per minute (33–296 bpm in wake maned wolves), which match the present case, as well as reported respiratory rate ranges, between 10 and 50 breaths per minute (Alves et al., 2023; Bronson et al., 2021; Furtado et al., 2006; Moraes et al., 2021; Rodden et al., 2012). Reported rectal temperature can range between 36.2 and 40.1°C during anaesthesia (Alves et al., 2023; Bronson et al., 2021; Furtado et al., 2006), although preferred rectal temperature is $37.7 \pm 1^\circ\text{C}$, which nearly matches the values in this report.

The use of reversible drugs allows a quick recovery once the procedure ends, reducing the possible risks of an unnecessary and prolonged anaesthesia. Whenever the situation permits, it is also suggested to keep crystalloid fluid therapy during any procedure (Orozco et al., 2015).

4.3 | Haematology and blood chemistry

Comparing the data obtained for the present work with the data recorded by Orozco et al. (2015), May-Junior et al. (2009) and Teare (2012), on average, the red series matches the second and third sampling. The haemoglobin value in the first sampling was decreased, but in the second and third sampling, it was already close to the averages presented by the cited authors. Haematocrit in the first sampling was very low, but by the second and third sampling, it was already close to the averages, even reaching the upper ranges during the third sampling. According to the average values, the red blood cell count also showed a decreased value in the first sampling, which was increasing in the second sampling, matching values of individuals in captivity (Da Silva Gomes, 2007) and reaching the average values during the third sampling. Comparing the erythrocyte count of the first sampling, when the specimen was approximately 5 months old, and considering that it had direct free-living origin, with the values obtained from animals within the Serra da Canastra National Park (May-Junior et al., 2009), the value is within the reference range reported for the species. Regarding hema-

**FIGURE 14** Female maned wolf rescued in Paraguay in 2020–2021, observing from the distance following reintroduction.

cytometric values (MCV, MCH, MCHC), the data obtained were within the ranges, but not always reaching the average value.

As for the leukocyte count, the second and third sampling results were close to the averages, the first sampling resulting below the general average, but within the range obtained in subadult individuals (Orozco et al., 2015). In general, the values obtained for lymphocytes, monocytes and eosinophils correspond with the average values published by Teare (2012). Basophil values match those reported by

Orozco et al. (2015) for females and for subadult individuals. Platelet values varied between the first and the subsequent samplings but were in the range published by Teare (2012). Total solids values were in range during the three samplings.

With regard to blood chemistry, creatinine values on both samplings were higher than the reported reference values but were in range when compared to a study done with captive maned wolves in northeastern Argentina (Mussart et al., 2003). Urea-reported values within the reference ranges and alanine aminotransferase were within range when compared to the three studies, even close to the mean value reported by Teare (2012). Albumin values were within the ranges reported by Teare (2012) and Orozco et al. (2015) but close to the minimum value, and even lower than the minimum reported by May-Junior et al. (2009) for sub-adults. Alkaline phosphatase reports very wide ranges according to Orozco et al. (2015) and Teare (2012), and the values obtained in the present study fall between the range, although not near the mean values.

4.4 | Serology for infectious diseases

Wild carnivores are increasingly exposed to pathogens that potentially threaten conservation efforts, as well as posing a risk to public health due to the risk of spill-over to domestic animals and human populations (Silva Pinto et al., 2010). Performing a passive surveillance on these animals gives opportunity to understand the eco-epidemiology of pathogens that are known to cause disease in this species but also to detect pathogens not yet reported in the species.

Ruling out canine distemper infection in the specimen was important as it has already been documented and associated to the death of captive specimens in Brazil (Cubas, 1996; Maranhão et al., 1991; Monteiro et al., 2010) and Chile (Vergara-Wilson et al., 2021). A work from Argentina reported that two wild specimens presented histopathological evidence compatible with canine distemper infection (Lertora et al., 2008), and works from Bolivia (Deem et al., 2012) and Brazil (Curi et al., 2012) found medium and high seroprevalences of distemper virus in wild specimens. The animal was found near the living quarters of a cattle ranch, with a high probability of close contact with domestic dogs, which are frequently associated with the introduction of the virus into natural environments (Monteiro et al., 2010). The negative result to immunochromatographic test for qualitative detection of viral antigen (Table 4) can mean, of course, that the animal was not hosting the virus at the moment, which in this case matched the clinical findings, although the enamel hypoplasia (Figure 3) could be associated to a prior infection. Although the animal in this case did not develop clinical signs related to an active infection during the rehabilitation process, as the negative result suggested, this test has been reported to provide false negative results when using blood serum samples, associated mainly to the large amounts of viral antigen required to produce a clear positive result, so a real-time nested PCR is the recommended test to rule out presence (or infection) of canine distemper virus (An et al., 2008; Fischer et al., 2013). Vaccination of dogs in rural environments can reduce the viral shedding and transmission of the disease to

wildlife, and unlike captive maned wolves, vaccinating wild carnivores is still a complex issue that has to be studied further (Loots et al., 2017; MWSSP, 2007).

Parvovirus is a highly contagious infectious disease caused by canine parvovirus that causes an acute and severe gastrointestinal haemorrhage that can rapidly lead to death as reported in maned wolves (Diniz et al., 1999; Maia & Gouveia, 2002). Reports are variable, as low prevalence for canine parvovirus antibodies was reported in one study performed in Bolivia, but an earlier study reports high prevalence, as well as studies in Brazil that report medium to high prevalences although the animals tested showed no signs of disease (Curi et al., 2012; Deem & Emmons, 2005; Deem et al., 2012). The animal sampled in the present case resulted negative to the immunochromatographic test for the detection of canine parvovirus agent (Table 4), which was feared to be associated to the diarrhoea the patient presented. This does not rule out the possibility of a previous exposure to the pathogen, which could be assessed in further cases through serum antibody testing. High serum antibody concentrations have been suggested to reduce faecal virus load, as circulating antibodies might inhibit the colonisation of the gastrointestinal epithelium, which can lead to false negative antigen results (Proksch et al., 2015). Vaccination of dogs that can be in contact with wild carnivores can help by significantly reducing the viral shedding (Freisl et al., 2017).

Toxoplasmosis is caused by intestinal coccidians associated to felines and is of great concern in public health (Hendrix & Robinson, 2012). Reports in maned wolves mention between 33% and 88% animals tested positive for toxoplasma antibodies (Curi et al., 2012; Deem & Emmons, 2005; Deem et al., 2012; Mattos et al., 2008; Orozco et al., 2013; Oliveira et al., 2016). The animal in this case tested negative to *T. gondii* antibodies (Table 4). Even in the case of a positive serology to *Toxoplasma* spp. antibodies, this would indicate exposure of the animal to different sources of the pathogen, such as environmental contamination by sporulated oocysts and prey infected with tissue cysts, such as small and medium-sized mammals (Oliveira et al., 2016), and not necessarily an active infection with risk of transmission, although close contact with human population and their associated domestic (and feral) carnivores increases the chances of disease transmission (Oliveira et al., 2016).

Disease caused by *D. immitis*, a nematode, is associated to heart disease and chronic helminthiasis of the circulatory system in dogs as well as in maned wolves (Carvalho & Vasconcellos, 1995; Hendrix & Robinson, 2012). The animal in this case tested negative to *D. immitis* antigen (Table 4), which could be analysed in a nationwide context with data from domestic dogs and captive wild carnivores as surveillance reports in other countries mention up to 85% of maned wolves positive to heartworm antigen (Deem et al., 2012; Orozco et al., 2013), although these data are still not available for Paraguay.

The animal sampled in this report was tested for 8 *Leptospira interrogans* serovars: *Grippotyphosa*, *Tarasovi*, *Hardjo*, *Pyrogenes*, *Wolffi*, *Canicola*, *Pomona* and *Ictero*. Positive results were reported for *Grippotyphosa*, *Wolffi* and *Ictero* during the first sanitary check-up and for *Grippotyphosa* and *Pomona* during the second check-up (Table 5). The serovars *Grippotyphosa* and *Wolffi* have been reported, with the same

titres, in maned wolves associated to human settlements and contact with domestic dogs that showed high seroprevalence (Orozco et al., 2013). Regarding the differences between both samplings, in another study, the results of several tests performed on a group of free-living maned wolves, one individual, female, tested positive for *Grippytyphosa* (1/100) during one sampling, but tested negative in four subsequent samplings (Deem et al., 2012). It has been suggested that specific antibodies are often short-lived (Orozco et al., 2013). Another individual, male, tested positive for *Ictero* (1/200), whereas the rest of the group ($n = 12$) tested negative during various samplings (Deem et al., 2012). Unlike clinical disease seen in canines and humans, the health impact of leptospirosis in wildlife is unclear and many free ranging canids are seropositive to various *L. interrogans* serovars without showing illness or functioning as important reservoirs (Deem & Emmons, 2005; Grimm et al., 2020; Zele-Vengust et al., 2021). Collection of urine sample to detect shedding of *Leptospira* organisms could allow the assessment of an animals' infectious status (Grimm et al., 2020; Zele-Vengust et al., 2021). The results obtained in this case can be considered low titres, although this is not clearly defined when interpreting wildlife results. Differences between studies might be due to inconsistencies in cut-off titres, serovars evaluated, characteristics of sampling sites, climate or geographical location and time of year of the study (Grimm et al., 2020). Lowering the cut-off titre could result in false positives, and taking a higher cut-off titre would result in a reduction of serovars detected (Grimm et al., 2020). Up to five serovars were detected in studies performed in Bolivia and Brazil (Correa et al., 2004; Deem et al., 2012; Deem & Emmons, 2005; Orozco et al., 2013; Silva Pinto, 2010; Esteves et al., 2022), and the pathogen has been associated to nephritis in captive maned wolves (Diniz et al., 1999); however, the real role of carnivores in the leptospirosis cycle, the significance of the findings of positive antibodies to a few serovars and its impact on free-living populations are still unknown (Deem & Emmons, 2005; Silva Pinto et al., 2010).

Regarding *Brucella* spp., the animal tested in this case reported a negative result to *B. canis* antibodies (Table 4), which is the standard screening test. This pathogen is constantly surveilled for in the species, although only two studies reported the presence of antibodies in serum, and none remained positive in the confirmatory tests (Antunes et al., 2010; Deem & Emmons, 2005; Deem et al., 2012; Kida, 2013). Although the maned wolves could be exposed to the pathogen through direct or indirect contact with domestic or feral dogs, there are no reports of the pathogen being detected in the species, and false positive serologic test results are suspected as cross-reactions with other gram-negative bacteria are a major issue (Antunes et al., 2010).

It has to be taken into consideration that, although the animal did not necessarily exhibit clinical signs compatible with the targeted pathogens, the tests performed are validated for domestic canines and might not be validated specifically for the species, which may cause false negatives or false positives in other cases.

Other pathogens that can be considered for future sampling in the species in Paraguay include various types of Adenovirus (Curi et al., 2012; Deem & Emmons, 2005; Deem et al., 2012; Maia & Gouveia, 2002; Orozco et al., 2013), canine coronavirus (Curi et al.,

2012; Deem & Emmons, 2005; Orozco et al., 2013), canine parainfluenza virus (Curi et al., 2012), tuberculosis (Maia & Gouveia, 2002), *Ehrlichia canis* (Oliveira et al., 2016), *Neospora caninum* (Mattos et al., 2008; Oliveira et al., 2016) and rabies (Deem & Emmons, 2005), as they already have reported positive serologic results or disease in the species.

4.5 | Dermatology

Thorough skin examination of the individual was important not only to rule out ectoparasites, but also skin pathologies caused by other microorganisms, or lesions that may be related to systemic diseases, or that can compromise the welfare of the animal, as one has to consider that transmissible diseases from domestic animals are one of the main threats to the species (de Paula et al., 2013).

The absence of skin alterations and lesions in this case, unlike those described in some reports (Bodini Santiago & Fernandes Oliveira, 2001; MWSSP, 2007), could be associated to a balanced and supplemented diet and environmental hygiene (Rodden et al., 2012; Marchegiani et al., 2020), which can also relate to the absence of fungal spores or ectoparasites that are mentioned in other reports (Arrais et al., 2021; Cansi et al., 2012; Fiori et al., 2023; Gilioli & Silva, 2000; Luque et al., 2014; Maia & Gouveia, 2002; Pereira et al., 2018). Daily cleaning of the enclosure and removal of faeces and leftover food items reduces the proliferation of vectors and other potentially pathogenic microorganisms (Rodden et al., 2012).

Dermatologic examination also allowed to rule out attack wounds from other animals (Miatello & Cobos, 2008), and no changes suggestive of neoplasia were found (Gamba et al., 2011; Gugelmin, 2022).

Special attention was to be paid to rule out infection by *Leishmania infantum*, which the species can host (Luppi et al., 2008) and is extremely relevant for conservation efforts and public health (Curi et al., 2006) considering the high prevalence in Paraguay (Noguera-Zayas et al., 2021). Infection by *Leishmania* spp. can cause skin lesions, although wild canids usually do not show the typical signs of canine leishmaniasis (Courtenay et al., 1994; Jusi et al., 2011), but it has been demonstrated that maned wolves can transmit the parasite to the invertebrate host (Mol et al., 2015).

4.6 | Traumatology and orthopaedics

Orthopaedic evaluation of the limbs in the species aids in detecting locomotor alterations that may be related to anatomic lesions that may or may not be radiologically detectable. The lameness detected in the patient was directly related to an infectious process, probably with a traumatic background, that was shown to be evolving positively. Although the thoracic limbs may be similar to those of domestic dogs, the morphology in this species is differentiated by the fact that this animal has elongated limbs and manual skills, as well as running and jumping (Pereira et al., 2019). The particular pacing of the species, as well as the hunting technique, requires correct limb use

(Bodini Santiago & Fernandes Oliveira, 2001; Presa et al., 2015; Soler et al., 2015).

The maned wolf evolved to have long enough legs to travel high enough above the ground level that resistance due to body contact with stiff plant stems is reduced (Dietz, 1984), and this has to be considered if the aim is to get the animal back to the wild. Thoracic and pelvic limb bones in this species, although much longer, are similar to those of domestic dogs, which can be helpful when evaluating them for diseases and deformities (Pereira et al., 2019; Siqueira et al., 2017, 2018).

Orthopaedic examination of the limbs assesses the joints and the range of movement (flexion and extension), palpation of muscle bodies, tendons and bones, where any discomfort has to be noted, as well as hyperextension and hyperflexion, which can indicate luxation (Arthurs, 2011). Any alteration in any segment of the anatomy of the limbs will be reflected in the movement of the animal, where the muscular bodies seek to balance the movement in relation to the forces that must be overcome to move in the environment, so the evaluation of the kinetics of movement can be an interesting tool in the evaluation (Arthurs, 2011; Aristizabal Escobar, 2015).

4.7 | Cytology

Cytology is a quick and inexpensive tool that can enormously help in diagnosing, not only when a pathology is suspected but also to screen for some specific pathogens. The fine needle aspirate cytology obtained from the right radius and ulna was suggestive of suppurative osteomyelitis associated with intralesional bacillary bacteria, which was confirmed in culture. This infection could have been related to an earlier trauma and was receding at the time of sampling, probably due to the various antibiotic treatments and the low antibiotic resistance of the colonising bacteria, as in another case that involved *Staphylococcus sciuri* (Godoy et al., 2016). The administration of long-acting amoxicillin as first line of treatment, IM or SC, has shown to maintain constant inhibitory concentrations for sensitive bacteria for up to 48 h (Porta et al., 2015) which can be ideal for animals not comfortable with constant medication.

Fine needle aspirate of bone marrow and peripheral blood smear did not report any haemoparasites in this case. These were taken on more than one occasion, due to the constant reports of haemoparasites in the species (Arrais et al., 2021; Cubas, 1996; Cansi et al., 2012; Phair et al., 2012; Perles et al., 2019; Silveira et al., 2016), particularly *Leishmania* sp. (Jusi et al., 2011), as discussed in Section 4.5.

Regarding vaginal cytology, it can help evaluate both physiological and pathologic processes. It can direct as to the optimal time for breeding or artificial insemination, where a shift in cellularity can be observed; as it can also be indicative of pathologic changes related to infection or neoplasia (Antonov, 2017). Changes associated to sexual maturity start being evident around 8–9 months of age, as reported in the vaginal cytology in this case, and although first copulations occur around 1–2 years of age, the first successful breeding usually occurs around 34 months of age (MWSSP, 2007; Orozco et al., 2015).

4.8 | Urine

Routine urine analysis in this species is fundamental as one of the most widely recognised disorders afflicting captive maned wolves is cystinuria (Bovee et al., 1981; Dietz, 1984; de Oliveira & Mendes, 2007; Mussart & Coppo, 1999), which is also an important cause of death in captive individuals (Maia & Gouveia, 2002). The animal sampled in this case presented a urine pH of 7.0, and no cystine crystals were observed, which matches the suggestion to keep urine at a pH of over 7.0, as cystine solubility increases in alkaline urine (Osbourne et al., 1989) but, as urinary pH over 7.5 may predispose them to cystitis, it should be kept at that value or lower (Boniface, 1998). One study suggests that supplemental taurine can be provided, at concentrations recommended for domestic felids, as a means for the prevention of cystinuria-related clinical disease (Childs-Sanford & Angel, 2006). Urine density and the amount of protein in urine in this case (Table 6) matched the range reported by Mussart et al. (2003). If a specific reference value cannot be found for the species, routine urinary tests results can be compared with other *Canidae* as a reference (Mussart et al., 2003).

As blood may sometimes be more difficult to obtain, urine samples can be used to yield information on an individual's health, helping predict blood work abnormalities, even when it is collected from the enclosure floor, as some substrates will have minimal effect on the analysis (Myers, 2023).

4.9 | Ophthalmology

The maned wolf is a mainly nocturnal species (Bandeira de Melo et al., 2007), and although they rely heavily on audition and olfaction, for exploration and communication (Dietz, 1984), they also have very good eyesight, as one study suggests that they have behavioural and genetic trichromacy (Jotta, 2012). Before starting the ophthalmological evaluation, a distance examination is suggested, where the clinician can assess the animal's attitude and her ability to navigate the environment, as well as the conformation of the periorbital region, the orbit, size, position and movements of both eyes (Featherstone & Heinrich, 2013).

Regarding the IOP, the results obtained match the values reported by Carvalho et al. (2020) and Honsho et al. (2016), who measured the IOP and Schirmer tear test (STT) in 8 captive maned wolves in a Zoo in Brazil, and 10 captive maned wolves in a breeding centre in Brazil, respectively. Both reports mention that there was no significant difference between left and right eye, males and females, or adults or elders (Carvalho et al., 2020; Honsho et al., 2016). Comparing the results of the STT to the mentioned reports, the tear production matches that of both studies. The reports also mention that there was no significant difference between the left and right eye or between the sexes, but Carvalho et al. (2020) found weak-to-moderate negative correlation between age and STT values, whereas Honsho et al. (2016) found no correlations between tear test results and age trend. This difference, though, has to be studied further, with a greater number of animals.

A positive Jones test in this case suggested a physiological flow of the nasolacrimal system, although sodium fluorescein is commonly used topically for the detection of corneal ulcerations (Featherstone & Heinrich, 2013). On the other hand, the negative Rose Bengal stain indicates normal tear film components protecting the epithelial cells from the dye, such as mucin and albumin, which is used to detect tear film disorders and superficial epithelial abnormalities (Featherstone & Heinrich, 2013).

Samples for cytological analysis, as described in a study in Brazil (de Oliveira Garcia et al., 2021), were not taken but can be considered in further studies. These samples can help understand the ocular physiological and pathological responses in the species (de Oliveira Garcia et al., 2021).

4.10 | Mouth assessment

Examination of the oral cavity for early detection of problems is particularly important since preventing medical problems of the oral cavity preserves the efficiency of the digestive processes and, in turn, the health of the animal (Pachaly & Gioso, 2001). Regarding the teeth, their shape, occlusion pattern and arrangement are, mostly, similar to that of domestic dogs, except for the absence of mandibular second molar observed in some individuals (Nalla, 2017). Capture of prey, food processing, fighting, intimidation, offspring transport and hair coat cleaning are the most important natural functions of a wild carnivore's teeth (Pachaly & Gioso, 2001), and the wide variety in the diet of the maned wolf may predispose to oral pathologies, as reported in free-living individuals in Bolivia (Deem et al., 2012).

Oral affections reported in maned wolves include gingival infections (Barboza et al., 1994), gingival hyperplasia (Montali & Kelly, 1989), teeth wearing (Lopez, 2009), tooth fracture (Furtado et al., 2007), unerupted canine teeth (Pessoa et al., 2016), caries (Emily & Eisner, 2021) and oral neoplasia (McNulty et al., 2000). Dental disease is likely associated with the dietary intake of acidic and sweet fruits, and tooth fractures may be related to chewing fruits with hard stones and perhaps armadillos (Deem et al., 2012). Dental radiographs are essential as they aid in the diagnosis of pathologies not always evident on examination, such as oligodontia, tooth fracture with retained roots, root fracture, periodontal disease, endodontic disease and neoplasia (Furtado et al., 2007; Niemiec, 2019). Determinations of anatomic references for anaesthetic blocks have been described for traumatology procedures of the mouth in this species (Souza Junior, 2016).

4.11 | Ultrasound

Ultrasound evaluations allow the characterisation of the positioning, dimensions, echogenicity and echotexture of the abdominal and pelvic organs, aiding in the diagnosis through the detection of anatomic, mainly, but also physio-pathologic alterations. The measurements obtained in the present case with regard to the thickness of the stomach walls (Figure 5) and the average thickness of the intestines, as well

as the contents of the gall bladder (Figure 4), match the measurements reported by Guimarães et al. (2013) in the ultrasound evaluations performed on five adult individuals, where they also refer to the difficulty in visualising the non-gravid uterus. Another work reports a bladder teratoma found through ultrasound evaluation (Fox et al., 2019).

The enterocolitis described during the first sanitary check-up (Figure 6) was associated with an excessive ingestion of mango fruit (*M. indica*) the days before the evaluation. Although infection by parvovirus was a differential diagnosis, antigen detection test proved negative (Table 4). Mango peel contains mangiferin, a xanthone, which has proved to be a prokinetic that stimulates normal gastrointestinal time (Morais et al., 2012). Although there have been reports of mango fruit-related salmonellosis outbreaks (Sivapalasingam et al., 2003), the diarrhoea in this case ceased immediately without specific treatment once the amount of mango in the diet was reduced.

Regarding the echocardiographic measurements, the values reported in this case for the left ventricular septal wall, in systole and diastole (LVSs and LVSd), left ventricular cavity, in systole and diastole (LVDs and LVDd) and left ventricular free wall, in systole and diastole (PLVWs and PLVWd), are lower than those reported by Estrada et al. (2009), who took echocardiographic and electrocardiographic measurements in 13 healthy, captive, anaesthetised adult maned wolves to provide reference information for the use in cardiac evaluation of the species. These changes may be because the individual studied was a juvenile, and the results published by Estrada et al (2009) were based on adult individuals. The mentioned study also concludes that echocardiographic findings are similar to those of the domestic dog.

Echocardiographic evaluation allows not only the measurement of the cardiac structures but also the assessment of normal functioning as there have been reports of physiologic valvular regurgitation, as well as the detection of parasites, which may not always be detected through routine antigen and antibody tests (Estrada et al., 2009).

Ocular B-mode ultrasound in this case reported preserved intraocular structures. This test can be used to evaluate intraocular and orbital lesions and can allow the veterinarian to diagnose neoplastic lesions, lens abnormalities such as cataract formation, haemorrhage or inflammation in the vitreous, or retinal detachment, although acoustic artefacts may interfere with accurate interpretation of the ultrasound findings (Dietrich, 2013).

4.12 | X-rays

Radiographic evaluation in this case included thorax, abdomen, vertebrae and limbs. Thoracic limb evaluation reported a fracture in the distal third of the right radius and ulna, which was in the process of bone repair (Figures 10 and 12). According to several reports, limb fractures are frequent in the species, along with other pathologic processes (Brasil et al., 2013; Reid et al., 2005; Siqueira et al., 2017; Siqueira et al., 2018; Pereira et al., 2021).

The thoracic evaluation included right and left lateral views and ventrodorsal view, although the dorsoventral view can be used for heart examinations. These views allowed a correct examination of

the respiratory organs, cardiac silhouette, the main blood vessels associated with the heart and lungs, and ribs, as described for other canids (Brown & Brown, 2022). In these views, changes in the heart due to dirofilariasis, signs indicative of tuberculosis and lesions related to trauma could also be detectable (Backues, 2008; Bodini Santiago & Fernandes Oliveira, 2001).

Abdominal radiography included right and left lateral views, as well as ventrodorsal. These views allowed the examination of the small and large intestine, bladder and spine, where the enterocolitis detected in ultrasound was also perceived. These views have also been reported to detect gastric dilatation volvulus in captive specimens (Hinton et al., 2017). In an adult female, pregnancy, during the last 3 weeks of gestation, could have been detected in these views (Aitken-Palmer et al., 2017; MWSSP, 2007).

Radiography is a readily available and relatively inexpensive technology that is not only important for the diagnosis of fractures but may also aid in the detection of other pathological conditions described in the species, such as dirofilariasis (Bodini Santiago & Fernandes Oliveira, 2001), extra-osseous osteosarcoma (Reid et al., 2005), tuberculosis (Maia & Gouveia, 2002) or spondyloarthropathy (Rothschild et al., 2001).

4.13 | Copro-parasitology

The diagnosed diversity in the present case was low, considering the vast variety of parasite species reported in maned wolves (Dietz, 1984; Dib, 2019; Deem & Emmons, 2005; Gilioli & Silva, 2000; González et al., 2013; Natalini et al., 2021; Silveira et al., 2016), where the average diversity was more than two species. This difference can be related to the techniques used, form and means of conservation and sending of the samples, collection time and number of animals sampled.

One of the parasites found in the individual is morphologically compatible with the genus *Lagochilascaris* sp. (Figure 13), a zoonotic parasite (Campos et al., 2017) which has already been reported in related species such as bush dog (*Speothos venaticus*) (Volcán & Medrano, 1991), and other carnivores, some of whom they share habitat with (Brenes-Madrugal et al., 1972; Falcón-Ordaz et al., 2016; Sakamoto & Cabrera, 2002), but no reports were found in maned wolves. The infection by this parasite is closely related to the ingestion of wild rodents, which are part of the species' diet (Campos et al., 2017; Paçô et al., 1999).

Regarding the presence of *Balantidium coli*, this parasite is considered common in humans and pigs (Marti & Hale, 1986) and is transmitted mainly through the faeces of its common carriers (Basset et al., 1986). Some authors suggest the possibility of transmission of the parasite from water contaminated with faeces (Matamoros, 1982), so the presence of anthropogenic settlements with domestic animals could represent the main source of contagion (Petters, 2020).

The results, as seen in Table 8, show a progressive reduction in parasite load and diversity as the treatment with metronidazole and levamisole was administered, until no parasite was found after the

administration of praziquantel, fenbendazole and pyrantel pamoate. The combination of praziquantel, fenbendazole and pyrantel still reports high efficacy, although some parasites are reported to be resistant to some of the individual drugs as well as combinations (D'Ambrosio et al., 2022). These drugs, particularly benzimidazoles, have been reported as effective in treating infection by *Lagochilascaris* spp. (Barrera-Pérez et al., 2012; Campos et al., 2016), as well as ivermectin (Cardoso et al., 2020; Faccio et al., 2013).

The species is considered a wild reservoir and definitive host of *Diocotophyma renale* (Orozco et al., 2015); therefore, it is the most reported parasite for the species (Cansi et al., 2012; Di Nucci et al., 2020; González et al., 2013; Natalini et al., 2021; Oliveira et al., 2021), although it was not found in the present case.

Parasite load evaluation gains an important role in captive animals because, although the presence of parasites is rarely associated to disease, the diverse stressors that affect the animals can predispose to parasitic disease, as well as the contraction of parasitic diseases from close contact with domestic dogs (Cansi et al., 2012).

5 | CONCLUSIONS

Rehabilitating a wild animal poses many challenges, such as the expenses of captive management and specialised studies to ensure the animal's health. Through extensive testing, we were able to safely diagnose the animal's health status, which allowed us to justify its reintroduction. A multi-disciplinary approach allowed for a complete health evaluation and provided a wealth of data that can be useful for managing the species in captivity and conservation efforts in the country. This is the first recorded case of rescuing, rehabilitating and releasing a maned wolf in Paraguay. It is also the first documented health check of this species in the country. As such, we consider it a model for future maned wolf work in Paraguay. To our knowledge, this is the first report of *Lagochilascaris* spp. in a maned wolf. The protocol outlined in this study can serve as a basis for developing an action plan for the maned wolf in Paraguay.

AUTHOR CONTRIBUTIONS

Conceptualisation; data curation; investigation; project administration; supervision; visualisation; writing – original draft; writing – review and editing: Joerg Richard Vetter Hiebert. *Formal analysis; investigation; resources; writing – review and editing:* José Gaspar Petters Cabrera. *Data curation; investigation; resources; writing – review and editing:* Santhiago Benítez del Puerto, Roger González Vatteone, César Esteban Brítez Valinotti, Raquel Ramírez Diarte, Lilian Maria González González, Paola Osorio and Fátima Bracho. *Investigation; resources; writing – review and editing:* Marlene Florentín Morel. *Data curation; investigation; resources:* Diego Augusto Dacac Aguilera. *Data curation; supervision:* Carlos Coronel Díaz. *Investigation; resources:* Walter Cardozo. *Data curation; investigation:* Claudia Raquel Soto. *Data curation; investigation:* Nilsa Melissa Domínguez Barreto. *Conceptualisation; methodology; supervision:* Antonio Alejandro Sciabarrasi.

ACKNOWLEDGEMENTS

We gratefully acknowledge the support from Guadalupe Otto, Elfriede Hiebert, Dieter Vetter, and Rigoberto García, for the everyday work. Liliana Cabrera, Victor Valverde, Prof. Frederick Bauer (DVS – MADES), Eduardo Ramirez (DISVET), María Fátima Rodríguez (CEDIVEP), Prof. Adelaida Quintana (CursosVet), Félix Ali (FalCop), Héctor López (Don Bicho), and Ivan Marecos (DVS – MADES), for the assistance during the whole process. And Betina Mariño (Cátedra de Microbiología, Facultad de Ciencias Veterinarias, Universidad Nacional del Litoral), Alcides Sensevy (La Esmeralda), Marcela Orozco (IEGE-BA), Dante Di Nucci (Güira Oga), Marcos Butti (Universidad Nacional de la Plata), Anna Sturaro, Monserrat Heurich, Eric Munscher for the assistance in data analysis and the preparation of this article.

CONFLICT OF INTEREST STATEMENT

The authors declare no conflicts of interest.

DATA AVAILABILITY STATEMENT

The data that support the findings of this study are openly available.

ETHICS STATEMENT

The authors confirm that the ethical policies of the journal, as noted on the journal's authors guidelines page, have been adhered to. The handling of the animal was carried out in accordance with current animal welfare legislation in Paraguay.

ORCID

Joerg Richard Vetter Hiebert  <https://orcid.org/0000-0002-4665-2659>

Antonio Alejandro Sciabarrasi  <https://orcid.org/0000-0002-0601-3166>

PEER REVIEW

The peer review history for this article is available at <https://www.webofscience.com/api/gateway/wos/peer-review/10.1002/vms3.1395>.

REFERENCES

- Aitken-Palmer, C., Ware, L. H., Braun, L., Lang, K., & Joyner, P. H. (2017). Novel radiographic technique for pregnancy detection in the maned wolf (*Chrysocyon brachyurus*) without anesthesia. *Journal of Zoo and Wildlife Medicine*, 48(1), 204–207.
- Alves, D. C., Lopes, D. M., Lucas, N. D., Carrera, A. L. C., Tamamoto, B. K., Carneiro, L. F. L., Debiage, R. R., & Fukushima, F. B. (2023). Anestesia intravenosa parcial (AIVP) em uma lobo-guará (*Chrysocyon brachyurus*) neonata. *Acta Scientiae Veterinariae*, 51, 894.
- An, D. J., Kim, T. Y., Song, D. S., Kang, B. K., & Park, B. K. (2008). An immunochromatography assay for rapid antemortem diagnosis of dogs suspected to have canine distemper. *Journal of Virological Methods*, 147(2), 244–249.
- Antonov, A. L. (2017). Application of exfoliative vaginal cytology in clinical canine reproduction—A review. *Bulgarian Journal of Veterinary Medicine*, 20(3), 193–203.
- Antunes, J. M. A. P., Machado, G. P., Costa, L. F., Fornazari, F., Cipriano, J. R. B., Appolinário, C. M., Allendorf, S. D., Bagagli, E., Teixeira, C. R., & Megid, J. (2010). Comparison of infection by *Brucella* spp. in free-ranging and captive wild animals from São Paulo State, Brazil. *Journal of Venomous Animals and Toxins including Tropical Diseases*, 16, 654–658.
- Aragona, M., & Setz, E. Z. F. (2001). Diet of the maned wolf, *Chrysocyon brachyurus* (Mammalia: Canidae), during wet and dry seasons at Ibitipoca State Park, Brazil. *Journal of Zoology*, 254(1), 131–136.
- Areskoug, V. (2001). Utilisation of remnant dry-forest corridors by the native fauna in a pastoral landscape in the Paraguayan Chaco [Doctoral dissertation, Centrum för biologisk mångfald, Uppsala, Sweden].
- Aristizabal Escobar, A. S. (2015). *Análisis cinético de la locomoción en perros como metodología diagnóstica de enfermedades ortopédicas* [Tesis de grado, Universidad de La Salle, Bogotá, Colombia]. https://ciencia.lasalle.edu.co/medicina_veterinaria/42?utm_source=ciencia.lasalle.edu.co%2Fmedicina_veterinaria%2F42&utm_medium=PDF&utm_campaign=PDFCoverPages
- Arrais, R. C., Paula, R. C., Martins, T. F., Nieri-Bastos, F. A., Marcili, A., & Labruna, M. B. (2021). Survey of ticks and tick-borne agents in maned wolves (*Chrysocyon brachyurus*) from a natural landscape in Brazil. *Ticks and Tick-borne Diseases*, 12(2), 101639.
- Arthurs, G. (2011). Orthopaedic examination of the dog: 1. Thoracic limb. *In Practice*, 33(3), 126–133.
- AZA Canid Taxon Advisory Group. (2012). *Large canid (Canidae) care manual*. Association of Zoos and Aquariums.
- Backues, K. A. (2008). Mycobacterial diseases in carnivores. *Zoo and wild animal medicine* (pp. 294–298). WB Saunders.
- Bandeira de Melo, L. F., Lima Sabato, M. A., Vaz Magni, E. M., Young, R. J., & Coelho, C. M. (2007). Secret lives of maned wolves (*Chrysocyon brachyurus* Illiger 1815): As revealed by GPS tracking collars. *Journal of Zoology*, 271(1), 27–36.
- Barboza, P. S., Allen, M. E., Rodden, M., & Pojeta, K. (1994). Feed intake and digestion in the maned wolf (*Chrysocyon brachyurus*): Consequences for dietary management. *Zoo Biology*, 13(4), 375–381.
- Barrera-Pérez, M., Manrique-Saide, P., Reyes-Novelo, E., Escobedo-Ortegón, J., Sánchez-Moreno, M., & Sánchez, C. (2012). Lagochilascaris minor Leiper, 1909 (Nematoda: Ascarididae) in Mexico: Three clinical cases from the Peninsula of Yucatan. *Revista do Instituto de Medicina Tropical de São Paulo*, 54, 315–317.
- Basset, D., Gaumerais, F. I., & Basset-Pougnat, A. (1986). Intestinal Parasitoses in children of an Indian community of Bolivian altiplano. *Bulletin de la Societe de Pathologie Exotique et de ses Filiales*, 79, 237–246.
- Bodini Santiago, M. E., & Fernandes Oliveira, L. T. (2001). Order Carnivora, family Canidae (dogs, foxes, maned wolves)—Medicine. *Biology, medicine, and surgery of South American wild animals* (pp. 285–290). Wiley-Blackwell.
- Boniface, J. (1998). *Dietary control of cystinuria in maned wolves (Chrysocyon brachyurus)* [Doctoral dissertation]. University of Maryland.
- Bovee, K. C., Bush, M., Dietz, J., Jezyk, P., & Segal, S. (1981). Cystinuria in the maned wolf of South America. *Science*, 212(4497), 919–920.
- Brady, C. A., & Ditton, M. K. (1979). Management and breeding of maned wolves. *International Zoo Yearbook*, 19(1), 171–176.
- Brasil, F. B. J., Daneze, E. R., Moura, J. F., Lataro, R. A., de Campos, A. G., Dias, B. P., & Palazzo, E. L. (2013). Osteossíntese de rádio e ulna em lobo-guará (*Chrysocyon brachyurus*) ferido por projétil balístico—relato de caso. *Nucleus Animalium*, 5(2), 2.
- Brenes-Madrugal, R. R., Ruiz, A., & Frenkel, J. K. (1972). Discovery of *Lagochilascaris* sp. in the larynx of a Costa Rican ocelot (*Felis pardalis mearnsi*). *The Journal of Parasitology*, 58(5), 978.
- Bronson, E., Deem, S. L., Westermann, L. C. P., Alpire, S. A., & Emmons, L. H. (2021). Field anesthesia of the maned wolf (*Chrysocyon brachyurus*) in Bolivia. *The Journal of Wildlife Diseases*, 57(3), 618–622.
- Brown, M., & Brown, L. C. (2022). *Radiography for veterinary technicians* (7th ed.). Elsevier.
- Bueno, A. A., & Motta-Junior, J. C. (2006). Small mammal selection and functional response in the diet of the maned wolf, *Chrysocyon*

- brachyurus* (Mammalia: Canidae), in southeast Brazil. *Mastozoología Neotropical*, 13(1), 11–19.
- Bueno, A. D. A., Belentani, S. C. D. S., & Motta-Junior, J. C. (2002). Feeding ecology of the maned wolf, *Chrysocyon brachyurus* (Illiger, 1815) (Mammalia: Canidae), in the ecological station of Itirapina, São Paulo State, Brazil. *Biota Neotropica*, 2, 1–9.
- Campos, D. M. B., Barbosa, A. P., Oliveira, J. A., Barbosa, C. A. L., Lobo, T. F. C., Silva, L. G., Thomaz, D. V., & Peixoto, J. D. C. (2016). Evaluation of the therapeutic efficacy of levamisole hydrochloride on third-stage larvae of *Lagochilascaris minor* in experimentally infected mice. *Revista do Instituto de Medicina Tropical de São Paulo*.
- Campos, D. M. B., Barbosa, A. P., Oliveira, J. A. D., Tavares, G. G., Cravo, P. V. L., & Ostermayer, A. L. (2017). Human lagochilascariasis—A rare helminthic disease. *PLoS Neglected Tropical Diseases*, 11(6), e0005510.
- Cansi, E. R., Bonorino, R., Mustafa, V. S., & Rocha Guedes, K. M. (2012). Multiple parasitism in wild maned wolves (*Chrysocyon brachyurus*, Mammalia: Canidae) in central Brazil. *Comparative Clinical Pathology*, 21, 489–493.
- Cardoso, C. B., das Neves, J. H., & Amarante, A. F. (2020). *Lagochilascaris minor* (Nematoda, Ascarididae) in a domestic cat in a coastal city of the state of São Paulo. *Veterinary Parasitology: Regional Studies and Reports*, 19, 100372.
- Carvalho, C. M., Rodarte-Almeida, A. C., Beanes, A. S., Machado, M. T., & Galera, P. D. (2020). Ophthalmic contributions to assessing eyes of two neotropical canids: *Cerdocyon thous* and *Chrysocyon brachyurus*. *Veterinary Ophthalmology*, 23(3), 460–471.
- Carvalho, C. T. D., & Vasconcellos, L. E. (1995). Disease, food and reproduction of the maned wolf: *Chrysocyon brachyurus* (Illiger) (Carnivora, Canidae) in southeast Brazil. *Revista Brasileira de Zoologia*, 12, 627–640.
- Childs-Sanford, S. E., & Angel, C. R. (2006). Taurine deficiency in maned wolves (*Chrysocyon brachyurus*) maintained on two diets manufactured for prevention of cystine urolithiasis. *Zoo Biology: Published in affiliation with the American Zoo and Aquarium Association*, 25(2), 87–100.
- Coelho, C. M., de Azevedo, C. S., Guimarães, M. A. D. B. V., & Young, R. J. (2016). Environmental enrichment effect on fecal glucocorticoid metabolites and captive maned wolf (*Chrysocyon brachyurus*) behavior. *Journal of Applied Animal Welfare Science*, 19(4), 353–362. <https://doi.org/10.1080/10888705.2016.1161512>
- Coelho, C. M., de Azevedo, C. S., & Young, R. J. (2011). Behavioral responses of maned wolves (*Chrysocyon brachyurus*, Canidae) to different categories of environmental enrichment stimuli and their implications for successful reintroduction. *Zoo Biology*, 30, 1–17.
- Coelho, C. M., de Azevedo, C. S., & Young, R. J. (2012). Behavioral responses of maned wolves (*Chrysocyon brachyurus*, Canidae) to different categories of environmental enrichment stimuli and their implications for successful reintroduction. *Zoo Biology*, 31(4), 453–469.
- Correa, S. H. R., Vasconcellos, S. A., Morais, Z., Teixeira, A. A., Dias, R. A., Guimarães, M. A. B., Ferreira, F., & Ferreira Neto, J. S. (2004). Epidemiologia da Leptospirose em animais na Fundação Parque Zoológico de São Paulo. *Brazilian Journal of Veterinary Research and Animal Science*, 41, 189–193.
- Courtenay, O., Macdonald, D. W., Lainson, R., Shaw, J. J., & Dyes, C. (1994). Epidemiology of canine leishmaniasis: a comparative serological study of dogs and foxes in Amazon Brazil. *Parasitology*, 109(3), 273–279.
- Cubas, Z. S. (1996). Special challenges of maintaining wild animals in captivity in South America. *Revue scientifique et technique (International Office of Epizootics)*, 15(1), 267–287.
- Cummings, D., Brown, J. L., Rodden, M. D., & Songsasen, N. (2007). Behavioral and physiologic responses to environmental enrichment in the maned wolf (*Chrysocyon brachyurus*). *Zoo Biology: Published in affiliation with the American Zoo and Aquarium Association*, 26(5), 331–343.
- Curi, N. H. A., Mendes Coelho, C., Campos Cordeiro Malta, M., Vaz Magni, E. M., Lima Sabato, M. A., Soriano Araujo, A., Portela Lobato, Z. I., Costa Santos, J. L., & Andrade Santos, H. (2012). Pathogens of wild maned wolves (*Chrysocyon brachyurus*) in Brazil. *Journal of Wildlife Diseases*, 48(4), 1052–1056.
- Curi, N. H. D. A., Miranda, I., & Talamoni, S. A. (2006). Serologic evidence of *Leishmania* infection in free-ranging wild and domestic canids around a Brazilian National Park. *Memórias do Instituto Oswaldo Cruz*, 101, 99–101.
- D'ambrosio Fernandes, F., Rojas Guerra, R., Segabinazzi Ries, A., Felipetto Cargnelutti, J., Sangioni, L. A., & Silveira Flores Vogel, F. (2022). Gastrointestinal helminths in dogs: Occurrence, risk factors, and multiple antiparasitic drug resistance. *Parasitology Research*, 121(9), 2579–2586.
- Da Silva Gomes, M. (2007). Carnivora—Canidae. *Tratado de animais selvagens* (pp. 492–504). ROCA.
- Deem, S. L., Bronson, E., Angulo, S., Acosta, V., Murray, S., Robbins, R. G., Giger, U., Rothschild, B., & Emmons, L. H. (2012). Morbidity and mortality. *The maned wolves of Noel Kempff Mercado National Park* (pp. 78–89). Smithsonian Institution Scholarly Press.
- Deem, S. L., & Emmons, L. H. (2005). Exposure of free-ranging maned wolves (*Chrysocyon brachyurus*) to infectious and parasitic disease agents in the Noel Kempff Mercado National Park, Bolivia. *Journal of Zoo and Wildlife Medicine*, 36(2), 192–197.
- de Oliveira, L. T., & Mendes, M. G. (2007). Urolithiasis in the maned wolf (*Chrysocyon brachyurus*): Assessment of four clinical cases in captivity. *Brazilian Journal of Veterinary Research and Animal Science*, 44(5), 352–357.
- de Oliveira Garcia, D., Estrela, G. C., Soares, R. T. G., Paulino, D. Jr., Jorge, A. T., Rodrigues, M. A., de Castro Sasahara, T. H., & dos Santos Honsho, C. (2021). A study on the morphoquantitative and cytological characteristics of the bulbar conjunctiva of the maned wolf (*Chrysocyon brachyurus*; Illiger, 1815). *Anatomia, Histologia, Embryologia*, 50(3), 439–447. <https://doi.org/10.1111/ahc.12647>
- de Paula, R. C., Rodrigues, F. H. G., Queirolo, D., Jorge, R. P. S., Lemos, F. G., & de Almeida Rodrigues, L. (2013). Avaliação do risco de extinção do lobo-guará *Chrysocyon brachyurus* (Illiger, 1815) no Brasil. *Biodiversidade Brasileira*, 3(1), 146–159.
- Dib, L. V. (2019). *Helmintos e protozoários gastrintestinais em material fecal de mamíferos carnívoros e artiodáctilos do Parque Nacional de Itatiaia, Brasil* [Masters thesis, Programa de Pós-Graduação em Microbiologia e Parasitologia Aplicadas, Instituto Biomédico da Universidade Federal Fluminense].
- Dietrich, U. M. (2013). Ophthalmic examination and Diagnostics—Part 3: Diagnostic Ultrasonography. *Veterinary ophthalmology* (5th ed., pp. 669–683). John Wiley & Sons, Inc.
- Dietz, J. M. (1984). Ecology and social organization of the maned wolf (*Chrysocyon brachyurus*). *Smithsonian Contributions to Zoology*, 392, 1–51.
- Dietz, J. M. (1985). *Chrysocyon brachyurus*. *Mammalian Species*, 234, 1–4.
- Diniz, L. S. M., Lazzarini, S. M., & Angelo, M. J. (1999). Problemas médico-veterinários de Lobo-guará (*Chrysocyon brachyurus*) em cativeiro. *Revista de Educação Continuada em Medicina Veterinária e Zootecnia do CRMV-SP*, 2(2), 34–42.
- Di Nucci, D. L., Guerisoli, M. M., Sciabarrasi, A., Tittarelli, M., Natalini, M. B., Castillo Giraudo, M., & Orozco, M. (2020). Nuevos hallazgos y localidades de *Diocotophyme renale* (Nematoda, Enoplida, Diocotophymatidae) en *Chrysocyon brachyurus* (Carnivora: Canidae) para la República Argentina. *Notas sobre Mamíferos Sudamericanos*, 2, . <https://ri.conicet.gov.ar/handle/11336/135565>
- Emily, P. P., & Eisner, E. R. (Eds.). (2021). *Zoo and wild animal dentistry*. John Wiley & Sons.
- Esteves, F. M., Guerra-Neto, G., Girio, R. D. S., Silva-Vergara, M. L., & Carvalho, A. D. F. (2022). Detecção de anticorpos para *Leptospira* spp. em animais e funcionários do zoológico municipal de Uberaba, MG. *Arquivos do Instituto Biológico*, 72, 283–288.
- Estrada, A. H., Gerlach, T. J., Schmidt, M. K., Siegal-Willot, J. L., Atkins, A. L., Van Gilder, J., Citino, S. B., & Padilla, L. R. (2009). Cardiac evaluation of clinically healthy captive maned wolves (*Chrysocyon brachyurus*). *Journal of Zoo and Wildlife Medicine*, 40(3), 478–486.
- Faccio, L., Oliveira, C. B., Denardin, C. A., Tonin, A. A., Gressler, L. T., Dalla Rosa, L., Sampaio, L. C., Stainki, D. R., & Monteiro, S. G. (2013). Case

- report: Feline infection by *Lagochilascaris* sp. in the State of Rio Grande do Sul, Brazil. *Veterinary Parasitology*, 196(3–4), 541–543.
- Falcón-Ordaz, J., Iturbe-Morgado, J. C., Rojas-Martínez, A. E., & García-Prieto, L. (2016). *Lagochilascaris minor* (Nematoda: Ascarididae) from a wild cougar (*Puma concolor*) in Mexico. *Journal of Wildlife Diseases*, 52(3), 746–748.
- Featherstone, H. J., & Heinrich, C. L. (2013). Ophthalmic examination and Diagnostics—Part 1: The eye examination and diagnostic procedures. *Veterinary ophthalmology* (5th ed., pp. 533–613). John Wiley & Sons, Inc.
- Fiori, F., de Paula, R. C., Navas-Suárez, P. E., Boulhosa, R. L. P., & Dias, R. A. (2023). The sarcoptic mange in maned wolf (*Chrysocyon brachyurus*): Mapping an emerging disease in the largest South American Canid. *Pathogens*, 12(6), 830.
- Fischer, C. D. B., Ikuta, N., Canal, C. W., Makiejczuk, A., da Costa Allgayer, M., Cardoso, C. H., Lehmann, F. K., Fonseca, A. S., & Lunge, V. R. (2013). Detection and differentiation of field and vaccine strains of canine distemper virus using reverse transcription followed by nested real time PCR (RT-nqPCR) and RFLP analysis. *Journal of Virological Methods*, 194(1–2), 39–45.
- Fox, L., Hanley, C. S., Padilla, L. R., & Duncan, M. (2019). Bladder teratoma in a maned wolf (*Chrysocyon brachyurus*). *Open Veterinary Journal*, 9(3), 259–262.
- Freisl, M., Speck, S., Truyen, U., Reese, S., Proksch, A. L., & Hartmann, K. (2017). Faecal shedding of canine parvovirus after modified-live vaccination in healthy adult dogs. *The Veterinary Journal*, 219, 15–21.
- Furtado, M. M., Kashivakura, C. K., Ferro, C., Almeida, A. T., Silveira, L., Astete, S., & Lopes, F. M. (2007). Prevalence of crown trauma in free-ranging maned wolves (*Chrysocyon brachyurus*) in central Brasil. *Journal of Veterinary Dentistry*, 24(4), 231–234.
- Furtado, M. M., Kashivakura, C. K., Ferro, C., de Almeida Jácomo, A. T., Silveira, L., & Astete, S. (2006). Immobilization of free-ranging maned wolf (*Chrysocyon brachyurus*) with tiletamine and zolazepam in central Brazil. *Journal of Zoo and Wildlife Medicine*, 37(1), 68–70.
- Gamba, C. O., Damasceno, K. A., Ferreira, E., Malta, M. C. C., & Cassali, G. D. (2011). Tubulopapillary carcinoma of the mammary gland in a maned wolf (*Chrysocyon brachyurus*): Histopathological and immunophenotypical analysis. *Arquivo Brasileiro de Medicina Veterinária e Zootecnia*, 63, 1377–1381.
- Gilioli, R., & Silva, F. A. (2000). Frequency of parasites and Salmonella infection in captive maned-wolf, *Chrysocyon brachyurus*, kept in zoos at the State of São Paulo, Brazil. *Arquivo Brasileiro de Medicina Veterinária e Zootecnia*, 52, 337–341.
- Giordano, A. J., Giménez, D., Martínez, V., Rojas, V., Saldívar, S., Velilla, M., Ayala, R., López, J., Velázquez, M., Thompson, J. J., Cartes, J. L., del Castillo, H., Mujica, N., Weiler, A., Villalba, L., & Ramírez, F. (2017). Carnívora: los carnívoros. *Libro Rojo de los Mamíferos del Paraguay: especies amenazadas de extinción* (pp. 79–101). Editorial Creatio.
- Godoy, I. D., Moraes, D. F. D. S. D., Pitchenin, L. C., Rosa, J. M. A., Kaguyama, F. C., Silva, A. D. J. D., Dutra, V., & Nakazato, L. (2016). Antimicrobial susceptibility profiles of *Staphylococcus* spp. from domestic and wild animals. *Ciência Rural*, 46, 2148–2151.
- González, C. A., Milano, A. M. F., & Lunaschi, L. I. (2013). New findings of helminths parasites of *Chrysocyon brachyurus* (Carnívora: Canidae) in Argentina. *Neotropical Helminthology*, 7(2), 265–270.
- Grimm, K., Rivera, N. A., Fredebaugh-Siller, S., Weng, H. Y., Warner, R. E., Maddox, C. W., & Mateus-Pinilla, N. E. (2020). Evidence of *Leptospira* serovars in wildlife and leptospiral DNA in water sources in a natural area in east-central Illinois, USA. *The Journal of Wildlife Diseases*, 56(2), 316–327.
- Grogan, A., & Kelly, A. (2016). Rehabilitation and release. *BSAVA manual of wildlife casualties* (pp. 81–92). BSAVA Library.
- Gugelmin, G. A. (2022). *Hemangioma cavernoso cutâneo em lobo guará (Chrysocyon brachyurus): análise morfológica e imunohistoquímica*. Trabalho de Conclusão de Curso (Especialização em Anatomia Patológica Veterinária) – Universidade de Brasília.
- Guimarães, L. D., Hage, M. C., Paula, T., Borges, A., Carretta Junior, M., Oliveira, A. R., Carneiro, F. T., Silva, V. H. D., & Silva, C. C. F. T. (2013). Abdominal and pelvic ultrasound study of the maned Wolf (*Chrysocyon brachyurus*). *Pesquisa Veterinária Brasileira*, 33(2), 265–272.
- Hendrix, C. M., & Robinson, E. D. (2012). *Diagnostic parasitology for veterinary technicians-E-book*. Elsevier Health Sciences.
- Hinton, J. D., Padilla, L. R., Joyner, P. H., Schnellbacher, R., Walsh, T. F., & Aitken-Palmer, C. (2017). Gastric dilatation volvulus in adult maned wolves (*Chrysocyon brachyurus*). *Journal of Zoo and Wildlife Medicine*, 48(2), 476–483.
- Hoffman, W. A., Pons, J. A., & Janer, J. L. (1934). The sedimentation-concentration method in *Schistosomiasis mansoni*. *Puerto Rico Journal of Public Health and Tropical Medicine*, 9(3), 283–291.
- Honsho, C. S., Jorge, A. T., Oliveira, L. T., Paulino-Junior, D., Mattos-Junior, E., Nishimura, L. T., & Dias, W. O. (2016). Intraocular pressure and Schirmer tear test values in maned wolf (*Chrysocyon brachyurus*). *Pesquisa Veterinária Brasileira*, 36, 919–923.
- Instituto Brasileiro do Meio Ambiente e dos Recursos Naturais Renováveis–IBAMA. (2015, 30 de abril de). Institui e normatiza as categorias de uso e manejo da fauna silvestre em cativeiro, e define, no âmbito do IBAMA, os procedimentos autorizativos para as categorias estabelecidas. *Instrução Normativa*, N° 07.
- Jotta, P. D. A. C. V. (2012). Análise comportamental e genética da visão de cores do lobo-guará (*Chrysocyon brachyurus*). [Masters thesis, Programa de Pós-Graduação em Microbiologia e Parasitologia Aplicadas, Instituto Biomédico da Universidade Federal Fluminense].
- Jusi, M. M. G., Starke-Buzetti, W. A., Oliveira, T. M. F. D. S., Tenório, M. D. S., Sousa, L. D. O. D., & Machado, R. Z. (2011). Molecular and serological detection of *Leishmania* spp. in captive wild animals from Ilha Solteira, SP, Brazil. *Revista Brasileira de Parasitologia Veterinária*, 20, 219–222.
- Kasper, C. B., da Fontoura Rodrigues, M. L., Severo, M. M., Cherem, J. J., Azambuja, R. B., Queirolo, D., Junior, P. D. S., Moro, M. E. B., Silva, F. P. D., Carlos, I. R., Montes, M. A., Silva, L. G. D., & da Silva, L. G. (2023). The last and endangered maned wolves (*Chrysocyon brachyurus*) from southern Brazil and Uruguay: New records and spatial distribution modeling. *Studies on Neotropical Fauna and Environment*, 59(01), 1–11.
- Kida Hayashi, E. M. (2013). *Pesquisa de cinomose, parvovirose e brucelose em carnívoros selvagens de vida livre e caes domesticos da regio do Parque Nacional das Emas, Goiás* [Tesis de Maestría en Epidemiologia Experimental Aplicada a Zoonosis, Universidad de Sao Paulo, Sao Paulo, Brasil]. <https://www.teses.usp.br/teses/disponiveis/10/10134/tde-29042013-153257/en.php>
- Kraft, W. (1999). *Dosificación de medicamentos para perros y gatos*. Acribia.
- Langlois, D. K., Koenigshof, A. M., & Mani, R. (2020). Metronidazole treatment of acute diarrhea in dogs: A randomized double blinded placebo-controlled clinical trial. *Journal of Veterinary Internal Medicine*, 34(1), 98–104.
- Lertora, J. M., Mosqueda, M., Mohr, B., & Frias, M. (2008). Reporte de Distemper canino en aguará guazú (*Chrysocyon brachyurus*). *Sexta Reunión Argentina de Patología Veterinaria*. Facultad de Ciencias Veterinarias, Universidad Nacional del Nordeste.
- Loots, A. K., Mitchell, E., Dalton, D. L., Kotzé, A., & Venter, E. H. (2017). Advances in canine distemper virus pathogenesis research: A wildlife perspective. *Journal of General Virology*, 98(3), 311–321.
- Lopes, F. M. (2009). Oral and skulls evaluation of captive and wildlife maned wolves (*Chrysocyon brachyurus*). [Masters thesis, Faculdade de Medicina Veterinária e Zootecnia, Universidade de SaPaulo].
- Luppi, M. M., Malta, M. C., Silva, T. M., Silva, F. L., Motta, R. O., Miranda, I., Ecco, R., & Santos, R. L. (2008). Visceral leishmaniasis in captive wild canids in Brazil. *Veterinary Parasitology*, 155(1–2), 146–151.
- Luque, J. A. D., Muller, H., González, L., & Berkunsky, I. (2014). Clinical sings suggestive of mange infestation in a free-ranging maned wolf (*Chrysocyon brachyurus*) in the Moxos Savannahs of Bene, Bolivia. *Mastozoología Neotropical*, 21(1), 135–138.

- Maia, O. B., & Gouveia, A. M. G. (2002). Birth and mortality of maned wolves *Chrysocyon brachyurus* (Illiger, 1811) in captivity. *Brazilian Journal of Biology*, 62, 25–32.
- Maned Wolf Species Survival Plan (MWSSP). (2007). *Maned wolf husbandry manual*.
- Maranho, A., Esteves, C. R., Barbosa, G., Amaral, R. G., & Araujo, V. R. (1991). Ocorrência de cinomose em lobo-guará (*Chrysocyon brachyurus*), cachorro-do-mato (*Cerdocyon thous*) e coati (*Nasua nasua*) em cativeiro. *Proc. XV Congresso da Sociedade de Zoológicos do Brasil*. Arquivos da SZB, Ilha Solteira, Sao Paulo, No. 12.
- Marchegiani, A., Fruganti, A., Spaterna, A., Dalle Vedove, E., Bachetti, B., Massimini, M., Di Pierro, F., Gavazza, A., & Cerquetella, M. (2020). Impact of nutritional supplementation on canine dermatological disorders. *Veterinary Sciences*, 7(2), 38.
- Marti, O. G., & Hale, O. M. (1986). Parasite transmission in confined hogs. *Veterinary Pathology*, 19, 301–314.
- Massara, R. L., de Oliveira Paschoal, A. M., Hirsch, A., & Chiarello, A. G. (2012). Diet and habitat use by maned wolf outside protected areas in eastern Brazil. *Tropical Conservation Science*, 5(3), 284–300.
- Matamoros, Y. (1982). Notas sobre la biología del tepezcuintle, *Cuniculus paca*, Brisson (*Agouti paca*) (Rodentia: Dasyproctidae) en cautiverio. *Brenesia*, 19–20, 71–82.
- Mattos, B. C., Patrício, L. L., Plugge, N. F., Lange, R. R., Richartz, R. R., & Dittrich, R. L. (2008). Soroprevalência de anticorpos anti-*Neospora caninum* e anti-*Toxoplasma gondii* em canídeos selvagens cativos. *Revista Brasileira de Parasitologia Veterinária*, 17(1), 267–272.
- May-Junior, J. A., Songsasen, N., Azevedo, F. C., Santos, J. P., Paula, R. C., Rodrigues, F. H. G., Rodden, M. D., Wildt, D. E., & Morato, R. G. (2009). Hematology and blood chemistry parameters differ in free-ranging maned wolves (*Chrysocyon brachyurus*) living in the Serra da Canastra national park versus adjacent farmlands, Brasil. *Journal of Wildlife Diseases*, 45(01), 81–90.
- McNulty, E. E., Gilson, S. D., Houser, B. S., & Ouse, A. (2000). Treatment of fibrosarcoma in a maned wolf (*Chrysocyon brachyurus*) by rostral maxillectomy. *Journal of Zoo and Wildlife Medicine*, 31(3), 394–399.
- Miatello, R., & Cobos, V. (2008). Nuevos aportes sobre la distribución del aguará guazú (*Chrysocyon brachyurus*, Carnivora: Canidae) en las provincias de Córdoba y Santiago del Estero, Argentina. *Mastozoología neotropical*, 15(2), 209–213.
- Mol, J. P., Soave, S. A., Turchetti, A. P., Pinheiro, G. R., Pessanha, A. T., Malta, M. C., Tinoco, H. P., Figueiredo, L. A., Gontijo, N. F., Paixão, T. A., Fujiwara, R. T., & Santos, R. L. (2015). Transmissibility of *Leishmania infantum* from maned wolves (*Chrysocyon brachyurus*) and bush dogs (*Speothos veneticus*) to *Lutzomyia longipalpis*. *Veterinary Parasitology*, 212(3–4), 86–91.
- Montali, R. J., & Kelly, K. (1989). Pathologic survey and review of diseases of captive maned wolves (*Chrysocyon brachyurus*) and bush dogs (*Speothos veneticus*). *Erkrankungen Der Zootiere*, 31, 35–43.
- Monteiro, M. V. B., dos Santos, M. P., Costa, C. T. C., Whiteman, C. W., & Monteiro, F. O. B. (2010). Cinomose canina nos animais domésticos e silvestres. *Revista de Ciências Agrárias Amazonian Journal of Agricultural and Environmental Sciences*, 53(2), 216–223.
- Moraes, R. N., Laske, T. G., Leimgruber, P., Stabach, J. A., Marinari, P. E., Horning, M. M., Laske, N. R., Rodriguez, J. V., Eye, G. N., Kordell, J. E., Gonzalez, M., Eyring, T., Lemons, C., Helmick, K. E., Delaski, K. M., Ware, L. H., Jones, J. C., & Songsasen, N. (2021). Inside out: Heart rate monitoring to advance the welfare and conservation of maned wolves (*Chrysocyon brachyurus*). *Conservation Physiology*, 9(1), coab044.
- Morais, T. C., Lopes, S. C., Carvalho, K. M. M. B., Arruda, B. R., de Souza, F. T. C., Trevisan, M. T. S., Rao, V. S., & Santos, F. A. (2012). Mangiferin, a natural xanthone, accelerates gastrointestinal transit in mice involving cholinergic mechanism. *World Journal of Gastroenterology: WJG*, 18(25), 3207.
- Motta-Junior, J. C., Talamoni, S. A., Lombardi, J. A., & Simokomaki, K. (1996). Diet of the maned wolf, *Chrysocyon brachyurus*, in central Brazil. *Journal of Zoology*, 240(2), 277–284.
- Mussart, N. B., & Coppo, J. A. (1999). Cystine nephrolithiasis in an endangered canid, *Chrysocyon brachyurus* (Carnivora: Canidae). *Revista de Biología Tropical*, 47(3), 623–626.
- Mussart, N. B., Solís, G. A., Arzuaga, S. M., & Coppo, J. A. (2003). Determinaciones hematológicas y urinarias en aguará-guazú (*Chrysocyon brachyurus*) en cautiverio en el nordeste argentino. *Revista Veterinaria*, 14(1), 79–84.
- Myers, D. (2023). Urine as a monitor of large carnivore health. *Fowler's zoo and wild animal medicine current therapy* (Vol. 10, pp. 295–302). WB Saunders.
- Nalla, S. F. (2017). Dentição do *Chrysocyon brachyurus* (Illiger, 1815) e sua relação com a dieta.
- Natalini, M. B., Notarnicola, J., Sanchez Gavier, F., & Kowaleski, M. M. (2021). Helminth infracommunity in a maned Wolf, *Chrysocyon brachyurus*, from the humid Chaco, Argentina. *Parasitology International*, 82(1), 102303. <https://doi.org/10.1016/j.parint.2021.102303>
- National Zoological Park. & Smithsonian Institution. (2005). *Fecal consistency score for maned wolf* (Versión 3.0). <https://nagonline.net/6173/fecal-condition-scoring-resource-center/>
- Niemiec, B. (2019). Oral radiology and imaging. *Wigg's veterinary dentistry: Principles and practice* (pp. 41–61). John Wiley & Sons, Inc.
- Noguera Zayas, L. P., Rüegg, S., & Torgerson, P. (2021). The burden of zoonoses in Paraguay: A systematic review. *PLOS Neglected Tropical Diseases*, 15(11), e0009909.
- Oliveira, A. R., Santos, D. O., Pereira, F. M. A. M., Carvalho, T. P., Moreira, L. G. A., Soares Neto, L. L., Manguera, D. K. A., Mello, E. S., Paixão, T. A., & Santos, R. L. (2021). Diotrophomosis in a free-ranging maned Wolf (*Chrysocyon brachyurus*): Clinical-therapeutic, ultrasonographic and pathological aspects—Case report. *Arquivo Brasileiro de Medicina Veterinaria e Zootecnia*, 73(1), 197–202.
- Oliveira, S., de Mattos, P. S. R., Mattos, K. K., Rogério, H., Toppa, R. H., da Costa, A. P., Marcili, A., Giuli, J. I., Ferreira, S., Da, F., Krawczak, F. S., Labruna, M. B., Gennari, S. M., Fátima, H., & Pena, J. (2016). Presence of anti-*Toxoplasma gondii*, -*Neospora caninum*, -*Leishmania* spp. and-*Ehrlichia canis* antibodies in free-ranging maned wolves (*Chrysocyon brachyurus*) in the northeastern region of the state of São Paulo, Brazil. *Brazilian Journal of Veterinary Research and Animal Science*, 53(3), 243–250.
- Orozco, M., Di Nucci, D., & Torres, L. (2015). Sanidad en aguará guazú (*Chrysocyon brachyurus*). *El Aguará Guazú en la Argentina* (pp. 127–141). Fundación de Historia Natural Félix de Azara.
- Orozco, M., & González-Ciccía, P. (2015). Protocolo de manejo de ejemplares de aguará guazú (*Chrysocyon brachyurus*) decomisados. *El Aguará Guazú en la Argentina* (pp. 191–222). Fundación de Historia Natural Félix de Azara.
- Orozco, M. M., Ceballos, L. A., de la Cruz Pino, M., & Gürtler, R. E. (2013). Local threats and potential infectious hazards to maned wolves (*Chrysocyon brachyurus*) in the southeastern Argentine Chaco. *Mammalia*, 78(3), 339–349.
- Osborne, C. A., Polzin, D. J., Lulich, J. P., Kruger, J. M., Johnston, G. R., O'Brien, T. D., & Felice, L. J. (1989). Relationship of nutritional factors to the cause, dissolution, and prevention of canine uroliths. *Veterinary Clinics of North America: Small Animal Practice*, 19(3), 583–619.
- Pachaly, J. R., & Gioso, M. A. (2001). The oral cavity. *Biology, medicine, and surgery of South American wild animals* (pp. 457–463). Iowa State University Press.
- Paçõ, J. M., Campos, D. M. B., & Oliveira, J. A. D. (1999). Wild rodents as experimental intermediate hosts of *Lagochilascaris minor* Leiper, 1909. *Memórias do Instituto Oswaldo Cruz*, 94, 441–449.
- Padilla, L. R., & Hilton, C. D. (2015). Canidae. *Fowler's zoo and wild animal medicine* (Vol. 8, pp. 457–467). Elsevier.
- Paula, R. C., & DeMatteo, K. (2016). *The IUCN red list of threatened species: Chrysocyon brachyurus*. <https://dx.doi.org/10.2305/IUCN.UK.2015-4.RLTS.T4819A82316878.en>

- Pautasso, A. A. (2009). Estado de conocimiento y conservación del aguará guazú (*Chrysocyon brachyurus*) en la provincia de Santa Fe, Argentina. *Biologica*, 11, 1–121.
- Pereckienė, A., Kaziūnaitė, V., Vyšniauskas, A., Petkevičius, S., Malakauskas, A., Šarkūnas, M., & Taylor, M. A. (2007). A comparison of modifications of the McMaster method for the enumeration of *Ascaris suum* eggs in pig faecal samples. *Veterinary Parasitology*, 149(1–2), 111–116.
- Pereira, K. H. N. P., Oliveira, E. L. R., Gonçalves, R. A. B., Rolim, L. S., Neto, R. D. N. D., Castilho, M. S., Teixeira, C. R., & Rahal, S. C. (2018). Dermatophytosis caused by *Microsporum canis* in a free-living Maned Wolf (*Chrysocyon brachyurus*). *Acta Scientiae Veterinariae*, 46, 4–4.
- Pereira, S. G., Borges, D. C. S., Monteiro, E. M., Cardoso, S. R. A., Silva, A. L., & Santos, A. L. Q. (2019). Anatomia óssea e muscular do antebraço e mão de *Chrysocyon brachyurus* (carnívora, canidae). *Revista Brasileira de Ciência Veterinária*, 26(4), 118–127.
- Pereira, S. G., Borges, D. C. S., & Santos, A. L. Q. (2021). Correlações biométricas entre o tamanho do antebraço e da mão de lobo-guará-*Chrysocyon Brachyurus* em diferentes situações de medições como subsídio para análises de pegadas. *Revista Brasileira Multidisciplinar*, 24(2), 67–87.
- Perles, L., Barranco, G. H. F., Soriano, I. M., Cruz, N. D. R. N., Bueno, P. J., Santana, Á. E., Machado, R. Z., Werther, K., & André, M. R. (2019). *Hepatozoon* sp. gamonts as an accidental finding in synovial liquid from an injured maned wolf (*Chrysocyon brachyurus*) in southeastern Brazil. *Revista Brasileira de Parasitologia Veterinária*, 28, 779–785.
- Pessoa, L., Roza, M., Farias, A., Jesus, P. H. D., Campbell, R. D. C., & Pinho, M. P. D. (2016). Extraction of unerupted maxillary canine teeth in a maned wolf (*Chrysocyon brachyurus*). *Case Reports in Veterinary Medicine*, 2016, 2827647.
- Petters Cabrera, J. G. (2020). *Prevalencias y cargas parasitarias en heces de Canis latrans, del APFF Médanos de Samalayuca*. Tesis de Maestría. Universidad Autónoma de Ciudad Juárez.
- Phair, K. A., Carpenter, J. W., Smee, N., Myers, C. B., & Pohlman, L. M. (2012). Severe anemia caused by babesiosis in a maned wolf (*Chrysocyon brachyurus*). *Journal of Zoo and Wildlife Medicine*, 43(1), 162–167.
- Porta, N., Prados, A. P., Kreil, V., Tarragona, L., Monfrinotti, A., & Rebuerto, M. (2015). Farmacocinética comparativa de una preparación de duración prolongada de amoxicilina luego de su administración por vía subcutánea e intramuscular a caninos. *In Vet*, 17(1), 17–23.
- Presa, M. F., González Ciccía, P., & Barzán, F. (2015). Comportamiento y cronobiología de aguará guazú (*Chrysocyon brachyurus*) en cautiverio. *El Aguará Guazú en la Argentina* (pp. 173–189). Fundación de Historia Natural Félix de Azara.
- Proksch, A. L., Unterer, S., Speck, S., Truyen, U., & Hartmann, K. (2015). Influence of clinical and laboratory variables on faecal antigen ELISA results in dogs with canine parvovirus infection. *The Veterinary Journal*, 204(3), 304–308.
- Queirolo, D., Moreira, J. R., Soler, L., Emmons, L. H., Rodrigues, F. H., Pautasso, A. A., Luis Cartes, J., & Salvatori, V. (2011). Historical and current range of the Near Threatened maned wolf *Chrysocyon brachyurus* in South America. *Oryx*, 45(2), 296–303.
- Queirolo, D., & Motta-Junior, J. C. (2007). Prey availability and diet of maned wolf in Serra da Canastra National Park, southeastern Brazil. *Acta Theriologica*, 52, 391–402.
- Reid, H. L., Deem, S. L., & Citino, S. B. (2005). Extrasosseous osteosarcoma in a maned wolf (*Chrysocyon brachyurus*). *Journal of Zoo and Wildlife Medicine*, 36(3), 523–526.
- Rivera, J. A., Arias, P. A., Sörensson, A. A., Zachariah, M., Barnes, C., Philip, S., Kew, S., Vautard, R., Koren, G., Pinto, I., Vahlberg, M., Singh, R., Raju, E., Yang, S., Yang, W., Vecchi, G. A., Harrington, L. J., & Otto, F. E. (2022). *Climate change made record breaking early season heat in Argentina and Paraguay about 60 times more likely* (Scientific Report). World Weather Attribution.
- Rodden, M., Siminski, P., Waddell, W., Quick, M., Maslanka, M., & Henry, B. (2012). *Large canid (Canidae) care manual*. Association of Zoos and Aquariums.
- Romero, V. L., & González, C. A. (2015). Guía para el registro de medidas morfológicas de ejemplares de aguará guazú. *El Aguará Guazú en la Argentina* (pp. 214). Fundación de Historia Natural Félix de Azara.
- Rothschild, B. M., Rothschild, C., & Woods, R. J. (2001). Inflammatory arthritis in canids: Spondyloarthropathy. *Journal of Zoo and Wildlife Medicine*, 32(1), 58–64.
- Sakamoto, T., & Cabrera, P. A. (2002). Subcutaneous infection of *Lagochilascaris minor* in domestic cats from Uruguay. *Veterinary Parasitology*, 108(2), 145–152.
- Salinas, P., Núñez, K., Ortiz, F., Zárate, G., Mendoza, M., & Weiler, A. (2022). Mamíferos medianos y grandes en campos de cultivo de arroz en los departamentos de Misiones e Itapúa, Paraguay. *Reportes científicos de la FACEN*, 13(1), 10–19.
- Santos, E. F., Setz, E. Z., & Gobbi, N. (2003). Diet of the maned wolf (*Chrysocyon brachyurus*) and its role in seed dispersal on a cattle ranch in Brazil. *Journal of Zoology*, 260(2), 203–208.
- Silva Pinto, J. R., & da Silva Pinto, J. M. L. (2014). Carnívora—Canidae. *Tratado de animais selvagens* (2ª ed., pp. 764–778). ROCA.
- Silva Pinto, J. R., Lopes Rocha, F., May Junior, J. A., & Gonçalves Morato, R. (2010). Ocorrência de Patógenos em carnívoros selvagens brasileiros e suas implicações para a conservação e saúde pública. *Oecologia Australis*, 14(03), 686–710.
- Silveira, J. A. G., D'elia, M. L., de Oliveira Avelar, I., de Almeida, L. R., Santos Dos, H. A., de Magalhaes Soares, D. F., Ribeiro, M. F., Dos Santos Lima, W., & Ecco, R. (2016). *Rangelia vitalii* in a free-ranging maned wolf (*Chrysocyon brachyurus*) and co-infections. *International Journal for Parasitology: Parasites and Wildlife*, 5(3), 280–285.
- Siqueira, R. C., Rahal, S. C., Inamassu, L. R., Mamprim, M. J., Felix, M., Castilho, M. S., Mesquita, L. R., Ribeiro, V. L., Teixeira, C. R., & Rassy, F. B. (2017). Osteology and radiology of the Maned Wolf (*Chrysocyon brachyurus*) pelvic limb. *Anatomia, Histologia, Embryologia*, 46(6), 572–581.
- Siqueira, R. C., Rahal, S. C., Inamassu, L. R., Mamprim, M. J., Teixeira, R. H., Teixeira, C. R., Rassy, F. B., Mesquita, L. R., Monteiro, F. O. B., Felix, M., & Melchert, A. (2018). Radiographic determination of pelvic limb orthopaedic measurements in maned wolf (*Chrysocyon brachyurus*). *Anatomia, Histologia, Embryologia*, 47(6), 527–536.
- Sivapalasingam, S., Barrett, E., Kimura, A., Van Duyne, S., De Witt, W., Ying, M., Frisch, A., Phan, Q., Gould, E., Shillam, P., Reddy, V., Cooper, T., Hoekstra, M., Higgins, C., Sanders, J. P., Tauxe, R. V., & Slutsker, L. (2003). A multistate outbreak of *Salmonella enterica* Serotype Newport infection linked to mango consumption: Impact of water-dip disinfection technology. *Clinical Infectious Diseases*, 37(12), 1585–1590.
- Smith, P. (2022). Status and distribution of Paraguayan canids. *Canid Biology and Conservation*, 25, 1–12.
- Soler, L., Palacios González, M. J., & Casanave, E. B. (2015). Algunos aspectos sobre la biología, ecología y comportamiento del aguará guazú (*Chrysocyon brachyurus*) en la Argentina. *El Aguará Guazú en la Argentina* (pp. 43–57). Fundación de Historia Natural Félix de Azara.
- Souza Junior, P., de Moraes, F. M., de Carvalho, N. D. C., Canelo, E. A., Thiesen, R., & Santos, A. L. Q. (2016). Mandibular morphometry applied to anesthetic blockage in the maned wolf (*Chrysocyon brachyurus*). *Journal of Zoo and Wildlife Medicine*, 47(1), 91–97.
- Sumano López, H. S., & Ocampo Camberos, L. (2006). *Farmacología veterinaria* (3rd ed.). McGraw Hill.
- Sykes, J. E., & Papich, M. G. (2021). Antibacterial drugs. *Greene's infectious diseases of the dog and cat* (pp. 103–126). WB Saunders.
- Teare, J. A. (2012). Valores fisiológicos ISIS. *Manual para cuidado de grandes cánidos* (pp. 139–153). Asociación de Zoológicos y Acuarios.
- Vasconcellos, A. D. S., Guimarães, M. A. D. B. V., Oliveira, C. A. D., Pizzutto, C. S., & Ades, C. (2009). Environmental enrichment for maned wolves (*Chrysocyon brachyurus*): Group and individual effects. *Animal Welfare*, 18(3), 289–300.
- Vergara-Wilson, V., Hidalgo-Hermoso, E., Sanchez, C. R., Abarca, M. J., Navarro, C., Celis-Diez, S., Soto-Guerrero, P., Diaz-Ayala, N., Zordan, M., Cifuentes-Ramos, F., & Cabello-Stom, J. (2021). Canine distemper

- outbreak by natural infection in a group of vaccinated maned wolves in captivity. *Pathogens*, 10(1), 51.
- Villalobos, D., López-Islas, M., & Frutos-Nava, J. (2015). Estudio comparativo de tres métodos coproparasitológicos en el diagnóstico de parasitosis intestinales. Unidad de Especialidades Médicas. Estado de México. *Revista Sanidad Militar*, 69, 330–335.
- Volcán, G. S., & Medrano, C. E. (1991). Natural infection of *Speothos venaticus* (Carnívora: Canidae) by adult *Lagochilascaris* sp. *Revista do Instituto de Medicina Tropical de São Paulo*, 33, 451–458.
- Wayne, R. K. (1986). Developmental constraints on limb growth in domestic and some wild canids. *Journal of Zoology*, 210(3), 381–397.
- Zajac, A. M., Conboy, G. A., Little, S. E., & Reichard, M. V. (2021). *Veterinary clinical parasitology*. John Wiley & Sons.
- Žele-Vengušt, D., Lindtner-Knific, R., Mlakar-Hrženjak, N., Jerina, K., & Vengušt, G. (2021). Exposure of free-ranging wild animals to zoonotic *Leptospira interrogans* Sensu Stricto in Slovenia. *Animals*, 11(9), 2722.
- Zuercher, G. L., Gipson, P. S., & Hill, K. (2001). A predator-habitat assessment for felids in the inland Atlantic Forest of eastern Paraguay: A preliminary analysis. *Carnivore Conservation in the Twenty-first Century*, 18(4), 115.
- Zuercher, G. L., Gipson, P. S., & Stewart, G. C. (2003). Identification of carnivore feces by local peoples and molecular analyses. *Wildlife Society Bulletin*, 31, 961–970.

How to cite this article: Vetter Hiebert, J. R., Petters Cabrera, J. G., Benítez del Puerto, S., González Vatteone, R., Florentín Morel, M., Dacak Aguilera, D. A., Brítez Valinotti, C. E., Ramírez Diarte, R., González González, L. M., Coronel Díaz, C., Osorio, P., Cardozo, W., Bracho, F., Soto, C. R., Domínguez Barreto, N. M., & Sciabarrasi, A. A. (2024). Rescue and rehabilitation of maned wolf (*Chrysocyon brachyurus*) in Paraguay: Case description. *Veterinary Medicine and Science*, 10, e1395. <https://doi.org/10.1002/vms3.1395>